

## Follicular Unit Transplantation – 2005

Robert M. Bernstein, MD,\* and William R. Rassman, MD

\* Associate Clinical Professor of Dermatology, College of Physicians and Surgeons, Columbia University, New York, NY

### INTRODUCTION

Follicular Unit Transplantation has its origins in the single-strip harvesting and stereomicroscopic dissection techniques of Dr. Bobby Limmer. He began using these techniques in his own practice in 1988 and published them in “Elliptical Donor Stereoscopically Assisted Micrografting as an Approach to Further Refinement in Hair Transplantation” in 1994.[1] The term “follicular unit” and the conceptual framework for Follicular Unit Transplantation were introduced into the medical literature by Bernstein and Rassman in the 1995 paper “Follicular Transplantation” [2] and detailed in the paired articles, “Follicular Transplantation: Patient Evaluation and Surgical Planning” and “The Aesthetics of Follicular Transplantation” (1997). [3, 4]

Follicular units are the naturally occurring groups of one to four terminal hairs that are present in a person’s scalp. Each group also contains sebaceous glands, a neurovascular plexus, an erector pilorum muscle and occasional vellus hairs and is surrounded by a circumferential band of adventitial collagen, the perifolliculum.[5] The essence of Follicular Unit Transplantation (FUT) is to use these individual, follicular units exclusively in the hair restoration process.[2]

The concepts central to Follicular Unit Transplantation have been detailed in a previous issue of Dermatology Clinics and readers are encouraged to refer to that publication.[6] Follicular Unit Transplantation has now become the standard technique used for surgical hair restoration. According to an annual survey conducted in September 2003 by the International Society of Hair Restoration Surgery, 94% of the 121 members polled said they use follicular unit grafts. Only 15% reported using the traditional plug grafts. [7] It is of note, however, that despite the widespread adoption of the technique, some of the core ideas of FUT are still being actively debated. [8] The key concepts of Follicular Unit Transplantation [6] are:

#### **1) The follicular unit is a discrete anatomic/physiologic entity**

If one considers the follicular unit as a distinct anatomic and physiologic entity, then preserving the follicular unit during dissection is the logical way to ensure the naturalness of the transplant and maximize hair growth. The advantage of follicular units over other grafting techniques in insuring a totally natural result has been the main reason for its widespread acceptance. However, the question of whether using these units exclusively will insure maximum yield is still subject to debate. [9, 10]

It is not clear if single hair follicles, carefully dissected and placed into the recipient site, will grow as well as intact follicular units. However, from a practical standpoint, dividing follicular units increases the risk of follicular transection, with the divided units being more subject to

desiccation, warming and crush injury during graft placement.[11, 12] Since intact units will already produce a natural result, it is hard to make a case for their sub-division. The rare exceptions would be in eyebrow transplantation (since the eyebrows consist of all 1-hair follicular units) and in very small procedures where there are not enough 1-hair units to complete the hairline. It could be argued that using grafts larger than follicular units could potentially decrease the risk of injury, but this creates a less natural appearance and greater recipient wounding – a poor trade-off when dissection injury can be minimized by careful stereo-microscopic dissection.

## **2) Only individual follicular units should be used in the transplant procedure**

Follicular units are relatively compact structures, but are surrounded by substantial amounts of non-hair bearing skin. The actual proportion of non-hair bearing skin is approximately 50%, so that its inclusion in the dissection will have a substantial effect upon the outcome of the surgery. [13] When multiple follicular units are used (with the intervening skin included) these effects will be magnified. (Figure 1.)

The advantage of using individual follicular units is that the wound size can be kept to a minimum while the amount of hair that can be placed into it can be maximized. Having the flexibility to place up to 4 hairs in a tiny recipient site has important implications for wound healing, the transplant design, and the overall cosmetic impact of the surgery.

## **3) Recipient sites should be kept as small as possible**

Large incisions cause more damage to the cutaneous vasculature than small wounds and, although the blood supply of the scalp is extensively collateralized, damage to these vessels may still adversely affect local tissue perfusion. This becomes more significant when transplanting grafts in large quantities or when there are structural changes in the underlying connective tissue (i.e. that caused by ultraviolet radiation). Another advantage of small wounds is creating a “snug fit.”

Unlike a punch, which removes recipient connective tissue, a small needle-made incision, retains the basic elasticity of the recipient site. When a properly fitted graft is inserted, the recipient site will then hold it snugly in place. This “snug fit” has several advantages. During surgery, it minimizes popping, and the need for potentially traumatic graft reinsertion. After the procedure, it ensures maximum contact of the implant with the surrounding tissue, so that oxygenation can be quickly re-established. In addition, eliminating dead space minimizes the coagulum that forms around the graft and this, in turn, facilitates wound healing.

Large wounds cause cosmetic problems that include dimpling, pigmentary alteration, depression or elevation of the grafts, or a thinned, atrophic look. The key to a natural appearing hair transplant is to have the hair emerge from perfectly normal skin. The only way to ensure this is to keep the recipient wounds small.

## **4) Follicular units should be transplanted in large sessions**

There are several reasons to transplant large numbers of grafts in each session:

*Social issues* – large sessions allow the hair restoration to be completed as quickly as possible and allow the patient to appear normal during the process, since the whole area to be transplanted can be covered in each session.

*Planning for Telogen effluvium* – an inevitable aspect of hair transplant surgery is that the patient’s existing hair in and around the transplanted area has a chance of being shed as a result of the procedure. The hair that is at greatest risk of being lost is the hair that has already begun the process of miniaturization and, if this hair is at or near the end of its normal life span, it may not

return. One should transplant through (rather than around) an area that is highly miniaturized, since it is likely that this area will be lost by the time the transplant has grown in. One should also attempt to transplant enough follicular units so that the volume of transplanted hair is greater than the volume of hair that may be permanently lost after the shedding.

*Economizing the donor supply* – regardless of how impeccable the surgical technique, each time an incision is made in the donor area, and each time sutures are placed, hair follicles are damaged or destroyed. This damage can be minimized by a fewer total number of transplant sessions, by low wound tension, by keeping the sutures very close to the wound edges (so that they don't incorporate much hair-bearing tissue) and, in subsequent procedures, using the previous scar as the upper or lower boarder of the new excision.

*Enhancing the composition of follicular units* – in FUT, each graft represents one follicular unit. It follows that if we are to use only the naturally occurring individual units of 1 to 4 hairs, we are limited by their normal distribution in the scalp. With larger sessions, greater numbers of each type of unit will be generated and this will ensure that there will be enough 1-hair grafts to create the soft transition zone of the frontal hairline (without splitting units) and a sufficient number three- and four-hair grafts will be available to give the patient a full, rather than diffusely thin look.

#### **5) Follicular units have a relatively constant distribution in the scalp of 1 unit per mm<sup>2</sup>**

The relative constancy of the follicular unit density at 1/mm<sup>2</sup> has been observed after performing densitometry measurements on thousands of patients and has been observed histologically by Headington as early as 1982. [2,5] Although the follicular unit density is not exactly 1/mm<sup>2</sup>, it is close enough to this number in most Caucasian scalps that it can be useful in the surgical planning. It is significantly less in the dark skinned races and will decrease in everyone's scalp as one moves laterally from the densest part over the occiput, towards the temples. However, it explains the general observation that as hair density increases there will be more hairs per follicular unit rather than follicular units spaced more closely together.

The implication is that the same number of follicular units should generally be used to cover a specific size bald area regardless of the hair density of the patient. Transplanting a patient with low hair density, using the same number and spacing of follicular units as in a patient with high density, will help to ensure that there is proper conservation of donor hair for the long-term, even though the results will appear less full. If we try to give the patient with low density a "thick" look by combining units, one risks running out of donor hair.

#### **6) Strip Harvesting should be performed in single, rather than multiple strips**

Hair not only grows at an acute angle, but this angle varies in different parts of the scalp and in adjacent areas. Since the harvesting phase of the transplant is relatively "blind" and doesn't allow for complete control of these variations, single strip harvesting will minimize follicular transection, as it removes tissue with the minimum amount of cut surface area. Once the strip is harvested, stereo-microscopic dissection will prevent damage to the hair-bearing structures.

Follicular units can also be removed by direct extraction from the donor area using small punches, in a procedure called Follicular Unit Extraction (FUE). Although, this procedure is gaining popularity from its ability to avoid a linear donor scar, it has the dual disadvantages of being a relatively blind technique (so that there is a greater rate of transection) and of causing greater wounding than single-strip harvesting (in terms of absolute surface area). [14, 15]

#### **7) All dissection should be performed under stereo-microscopic control**

In order to keep follicular units intact and dissect them without damage, visibility is the key. Only stereo-microscope dissection allows their clear visualization in both normal and scarred skin, independent of the specific hair characteristics of color, hair shaft diameter, and curl.

## PATIENT SELECTION

In men, androgenetic alopecia is diagnosed by the characteristic “patterned” distribution of hair loss and by the presence of miniaturization in the areas of thinning. A family history of hair loss is supportive, but not necessary, for the diagnosis. [16] In women, the diagnosis is more difficult, since the most common presentation, a diffuse pattern, can be mimicked by a number of other medical conditions. The presence of miniaturized hair will aid in the diagnosis, but it is important to rule out non-androgenetic etiologies. Miniaturization, the progressive diminution of hair shaft diameter and length, in response to systemic androgens, is easily observed using a densitometer, a hand-held instrument that magnifies a small area of clipped scalp. (Figures 1, 2)

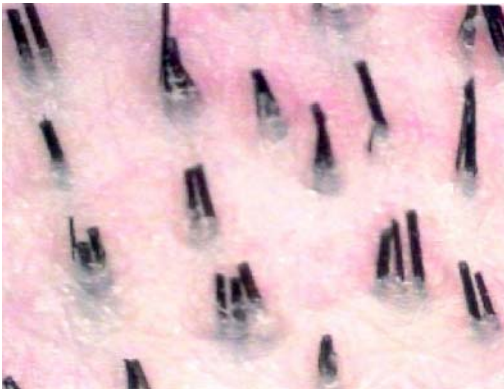


Figure 1. Normal scalp. Densitometry showing natural hair groupings (the surface manifestations of follicular units) in an area of where the hair is clipped to 1-mm. Two discrete populations of hair can be seen; larger terminal hair and scattered fine vellus hair.

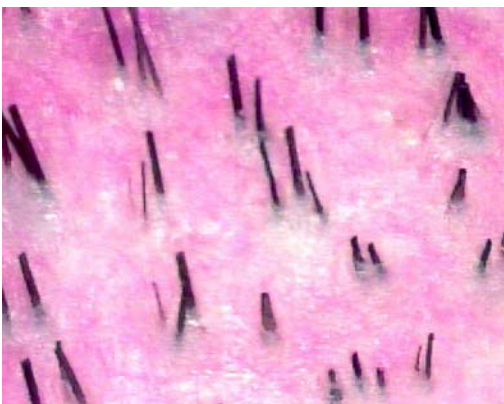


Figure 2. Miniaturization. Thick terminal hair, fine vellus hair, and hair of intermediate diameter (miniaturized hair) caused by the effects of systemic androgens on susceptible follicles.

The most widely used classification of male pattern hair loss is the one developed by Norwood [17]. In the common pattern, two areas of hair loss, a bitemporal recession and a

thinning crown, enlarge and eventually coalesce to form a large bald area that covers the entire front, top and crown (vertex) of the scalp. (Figure 3) In the Type A Variant, there is an anterior to posterior progression of the hair loss. (Figure 4) Although the sides and back tend to resist androgenetic changes, these areas may exhibit significant thinning in advanced age.

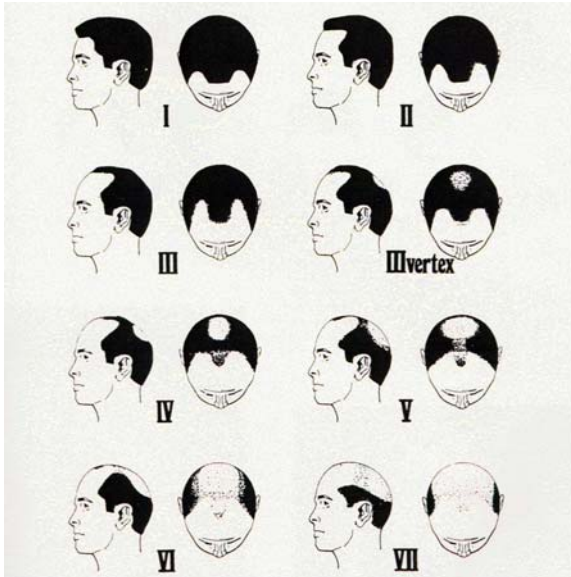


Figure 3. Norwood Classification – Common Type

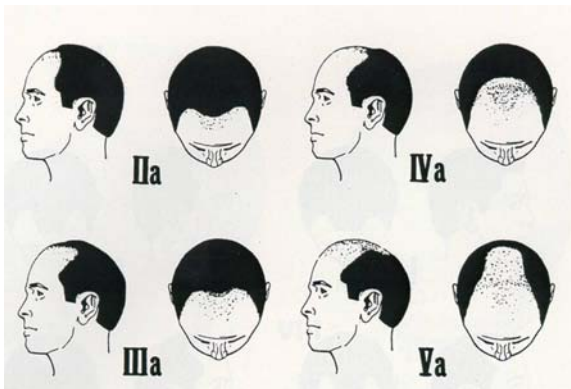


Figure 4. Norwood Classification – Type A Variant

Two other, less common types of genetic hair loss are, Diffuse Patterned Alopecia (DPA) and Diffuse Unpatterned Alopecia (DUPA) which manifest as diffuse thinning in the front, top and vertex. As with female pattern hair loss, these may mimic other conditions and pose both diagnostic and therapeutic challenges. It is important to distinguish between DPA (which has a stable donor area) and the less common DUPA (where the donor fringe continues to thin significantly over time), since patients with DUPA are not candidates for surgical hair restoration.

DUPA tends to advance faster than DPA and eventuate in a horseshoe pattern resembling the Norwood class VII. However, unlike the Norwood VII, the DUPA horseshoe can look almost transparent due to the low density of the back and sides. [3] The early signs of DUPA are: 1) a rapid decrease in hair volume (as distinguished from density) and a change in hair texture at an early age (often in the teens), 2) the maintenance of an adolescent hair pattern and persistent frontal hairline in spite of dramatic volume change, 3) a see-through donor area, which is greatly

accentuated when the hair is lifted up, 4) significant miniaturization of the donor area (>35%), and 5) a donor density  $\leq 1.5$  hairs/mm<sup>2</sup>.

If a diagnosis of DUPA is suspected, any decisions regarding surgical hair restoration should be postponed. The chance of missing the diagnosis of diffuse patterned alopecia argues strongly against performing hair transplantation at an early age. [18]

Although there are exceptions, it is generally best to wait until a person is 25 before considering surgical hair restoration. With the availability of effective medications for hair loss (finasteride and minoxidil) delaying surgery has become somewhat easier, since, in addition to growing or maintaining hair, they can be used to temporize the patient until hair transplantation is indicated. Barring untoward reactions, finasteride should always be used at least one year before judging its effectiveness. The patient should be warned that during the first 6 months, hair loss may be accelerated from these medications.

There are several important reasons not to perform surgery when a person is too young. First, the extent and rate of hair loss is more difficult to predict. Second, as discussed above, a diagnosis of DUPA may be missed. Third, the younger patient commonly wants his adolescent hairline and density restored. Restoring the hairline to its original position will look unnatural as the patient ages. Restoring a patient's original density, of course, is not a realistic goal of a transplant, which services only to redistribute existing hair. By the time a patient reaches his mid-20's he is more likely to be forward-looking and have expectations that can be satisfied with surgery.

### **Hair and Scalp Characteristics**

When assessing a patient with androgenetic alopecia, one generally focuses on the extent of balding, i.e. matching the patient's hair loss to a particular class on the Norwood scale and then anticipating how far he might progress considering his age, rate of hair loss, family history and use of medications. Possibly a more important consideration, however, is the patient's donor supply. If one assumes that balding is progressive and that the ultimate degree of hair loss is unknowable, then one should only treat patients who possess enough donor hair to complete the transplant in the event of extensive baldness. This would be particularly important when the patient has not yet reached middle age and the predictive powers of the physician are the weakest.

Three major factors determine a patient's donor supply; donor density, scalp laxity, and the physical size of the donor area. Hair characteristics, such as color, wave, and hair shaft diameter, also play a significant role, since a patient with good hair characteristics will obtain more coverage and a fuller appearance for the same absolute number of hairs transplanted, than someone with hair qualities that are less ideal. Light hair color, a wide hair shaft diameter and curly or wavy hair are attributes that will make the transplant look fuller.

The average Caucasian has approximately 175-275 hairs/cm<sup>2</sup> (approximately 80-120 follicular units/cm<sup>2</sup>). [8] For patients with average density and average hair characteristics, approximately half of the hair in the donor area may be moved without it appearing too thin. This will also provide enough coverage to camouflage the donor scar. Therefore, hair may be harvested from the donor area until the density approaches 100 hair/cm<sup>2</sup>. [2] As a general guide, virgin scalp should have a donor density of at least 150-180 hairs/cm<sup>2</sup> for surgical hair restoration to be considered, with the lower end of the range being reserved for the older patient or those with excellent hair characteristics. In non-Caucasians, the normal density is less, so the lower limit can also be adjusted downward. [4] To be a candidate for surgery, no more than 20% of the hair in the donor area should exhibit miniaturization.

Scalp laxity is another important factor in determining total available donor supply. Although difficult to quantify, a significantly greater amount of hair can be harvested from persons with loose scalps compared to those whose scalps are tight. The limitations of a tight scalp usually manifest itself after the first procedure so assessing scalp laxity at the outset can be difficult. Nevertheless, its assessment can not be over emphasized, since patients with tight

scalps can have a very limited donor supply and their long-term goals must be accordingly reduced.

Interestingly, patients with very loose scalps tend to heal with widened scars and this will also limit the amount of transplantable donor hair. [19] Follicular unit extraction (FUE), a harvesting method that does not require a linear donor incision, should be considered in cases of very loose and very tight scalps. Sometimes, however, FUE is difficult to perform in patients whose scalps are very loose. [14]

Finally, the physical dimensions of the donor area will affect the amount of transplantable hair. The mid-portion of the harvestable donor zone is generally at the level of the occipital protuberance and extends to within 3cm of the temple hairline on either side, a distance of approximately 33cm. It is important to keep the incision at this level, since an incision that is too high risks harvesting hair that may not be permanent and an incision that is too low increases the chance of a widened scar.

## PLANNING THE RESTORATION

The two key aesthetic landmarks are the frontal hairline and the vertex transition point. In a mature adult, the mid-portion of the frontal hairline rests approximately one finger-breadth (1.5-2 cm) above the upper brow crease and is the position to which most hairlines should be restored. One should generally not place the hairline at the level of the upper brow crease, since this is the position of the adolescent hairline and will be too far forward as the patient ages. The hairline should recede towards the temples, but there is more flexibility in designing the hairline at this location. [4]

The vertex transition point (VTP) separates the top of the scalp from the crown and is the most important posterior landmark to be considered when designing the transplant. The VTP is the point where the hair transitions from a predominately forward direction to form the radially oriented crown whorl. [20] Stopping at this point will allow the transplant to look natural even if the patient becomes extensively bald and no further procedures are performed. Fortunately, most people will have enough donor hair to reach this point. Extending the transplant beyond the vertex transition point should be reserved for patients with an above average donor supply. (Figure 5A, B) [21]

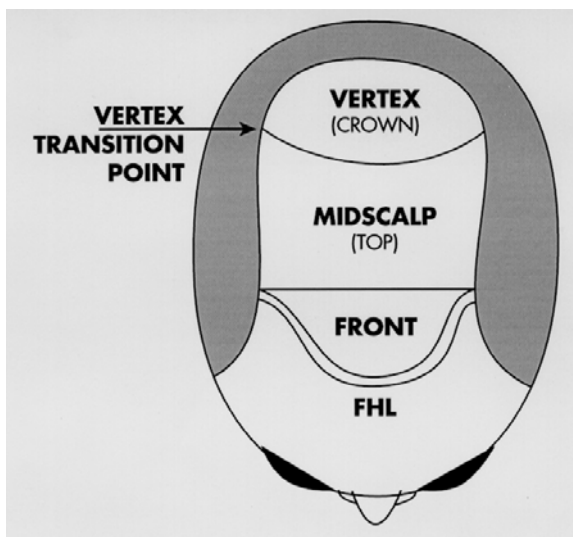


Figure 5A. Schematic of the regions of the scalp. The Vertex Transition Point is the part of the scalp where the hair changes from a predominantly forward direction to form the whorl.

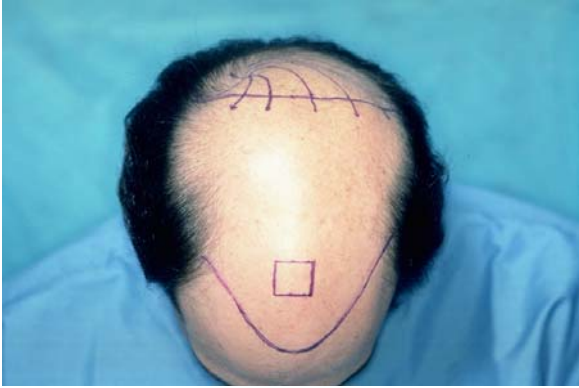

Figure 5B. Regions of the scalp. Note the predominately forward direction of hair markings as one crosses over the vertex transition point anteriorly.

In the first transplant session, the frontal hairline should be established and coverage should extend at least to the vertex transition point. Subsequent sessions should be used to achieve greater density or to address additional areas of hair loss. [4] In general, the goals should be achieved in as few sessions as possible to minimize the number of times the donor area is accessed and be the least disruptive to the patient's life.

With the exclusive use of follicular units and concomitant use of small recipient sites, the risk of vascular compromise in the recipient area is small, even with large sessions. That said, large sessions cannot be performed with impunity. In general, we recommend densities in the range of 20-25 follicular unit/cm<sup>2</sup> when large sessions are performed. Some doctors advocate the use of higher densities, particularly in virgin scalps; however, it is our view that this may increase the risk of vascular compromise, graft popping, desiccation and other problems that can adversely affect graft survival. Transplanting large number of grafts also increases the time the grafts remain outside the body and creates more demands on the staff, both in technical skills and in organization. Large sessions should not be performed by inexperienced physicians or those with limited surgical teams. [4]

Two important factors that affect the number and density at which grafts should be placed are photo damage of the recipient skin and smoking. Most doctors caution on photo-protection after surgery, but give little attention to the effects of existing sun damage on the procedure. It has been this author's personal observation that ultraviolet radiation alters the cutaneous vasculature so that the donor area is less able to support densely packed grafts. UV light also alters the collagen and elastic tissue so that grafts are held less securely. These factors need to be examined in well-controlled studies. The deleterious effects of smoking on wound healing have been well documented and the surgical planning in chronic smokers should be more conservative with respect to the density and the absolute numbers of grafts planted. [22]

Table 1 gives the recommended number of follicular unit grafts for the first hair transplant session organized according to the person's Norwood class. [2]

**Table 1. Number of Grafts in First Follicular Unit Transplant Session**

<u>Norwood Class</u>	<u>Follicular Units</u>	<u>Total Units with Crown</u>
III	800-1000+	---
III Vertex	800-1000+	1100-1300+
IIIa	1300-1600+	---
IV	1100-1400+	1500-1800+



IVa	1700-2100+	---
V	1500-1800+	1900-2400+
Va	2000-2400+	---
VI	2000-2400+	2400+
VII	2000-2400+	---

The second session should be planned no sooner than 8-12 months after the first session, since it takes this amount of time for the hair from the first session to grow and for the cosmetic impact to be appreciated. Once the transplanted hair has reached its full length, diameter, and texture, the physician and patient will be in the best position to decide on the placement of additional grafts. Waiting to perform the second procedure will also allow donor laxity to return, although it rarely goes back to its original state. Finally, if there is significant Telogen effluvium after surgery, it may take up to a year for that hair to regrow.

The second session is used to add density to areas transplanted in the first session and to add coverage to any additional areas of hair loss. During the second session, it is often helpful to refine the hairline, usually by making it more irregular. Extending the transplant into the crown might also be considered in the second session if the first procedure produced adequate coverage in the area anterior to the vertex transition point and if there are adequate donor reserves.

Generally, the restoration can be completed in two sessions. Additional sessions reserved for addressing further hair loss. The total number of graft needed for a complete restoration is indicated in Table 2. [3]

**Table 2. Total Number of Follicular Unit Grafts for a Complete Restoration**

<u>Norwood Class</u>	<u>Follicular Units</u>	<u>Total Units with Crown</u>
III	900-1500	---
III Vertex	900-1500	1300-2000
IIIa	1400-2200	---
IV	1200-2000	1700-3000
IVa	1800-3600	---
V	1700-3000	2100-4000
Va	2400-4400	---
VI	2200-4600	3000-5600
VII	2200-4800	4000-6600

## **PATIENT PREPARATION**

Besides its role in hair regrowth, or in retarding the progression of hair loss, finasteride is often prescribed pre-operatively to minimize the chance of post-surgical shedding. However reasonable this practice, there is currently little scientific data to support this use or to indicate how far in advance of surgery the drug should be given. Patients using topical minoxidil should discontinue the medication several days before surgery (because it is a vasodilator and may increase bleeding) and wait until a week after the procedure before resuming it (to avoid the irritating effects of its alcohol/propylene glycol base). If a patient has been on minoxidil for an extended period of time and does not plan to continue the medication after surgery, he should stop the medication several months prior to the procedure. In this way, if there is significant hair

loss, it may be accounted for in the surgical planning. On most hair transplant patients, finasteride should be continued long-term to help retard further balding.

To prevent damage to the grafts, patients who wear hair pieces should convert them to a tape-less, glue-less clip-on system that can easily be removed before showering and sleeping. The front edge of the piece can be kept in place with a stiffening-rod. Patients are encouraged to permanently discontinue the system after the procedure, but those who feel the need to use them until their hair grows in should wait at least five days post-op before wearing them and to use them as infrequently as possible.

Systemic antibiotics are not indicated for routine use in hair transplantation. For those with a history of endocarditis or mitral valve prolapse, one should refer to the review by Haas and Grekin regarding antibiotic prophylaxis and consult with the patient's primary physician. [24] In the peri-operative period, patients should, of course, abstain from smoking, alcohol and medications that will increase bleeding. There is no consensus on the necessity of routine blood testing before hair transplantation.

The morning of surgery patients are advised to shampoo with chlorhexidine and wear a button-down shirt. In the office, patients change into a cotton surgical gown and are photographed from the neck up, with front, top and occasionally three-quarter views. The hairline and, if appropriate, the vertex transition point and crown swirl are marked in gentian violet and additional photos are taken. All photographs (or their digital counterparts) are kept as part of patients' permanent medical record.

If there are no contraindications, patients who are not driving home after the procedure, are pre-medicated with diazepam 15 mg PO (adjusted for body weight) and an intramuscular injection of methylprednisolone 80 mg.

## **SURGICAL TECHNIQUES**

### **OR Setup**

The dissecting stereo-microscope is the most important tool for performing follicular unit transplantation [1, 9, 24]. There should be one microscope for each dissector at work stations with comfortable seating. Because the patient will be sitting for long periods of time, and the physician and staff will be working predominately on the top of the patient's scalp, the operating tables should provide lumbar support when patients are sitting and need to be low to the ground (the seat surface should be 22 inches from the floor). Bright fluorescent ceiling lights generate less heat than high intensity OR lights and minimize bleeding during the procedure.

Grafts should be stored on a stable surface, such as a counter top, that cannot inadvertently be knocked over. Grafts should be held in chilled normal saline or Lactated Ringer's and the solution should be kept on ice blocks or refrigerated. Limmer has shown a high survival rate for grafts kept in chilled saline up to eight hours. [25] To eliminate inadvertently placing grafts in the wrong patient, a small refrigerator for the grafts should be dedicated to each operating room.

### **Preparing for the Donor Harvest**

With the patient in an upright position, the hair in the donor area is trimmed to 1-2 mm using electric clippers. The hair should be cut so that the center of the shaved area is at the level of the occipital protuberance and extends laterally over the ears. When harvesting a 1 cm wide strip, several millimeters should be trimmed on either side to facilitate suturing.

In calculating the strip length for Caucasian patients, it can be assumed that each 1 cm<sup>2</sup> of donor tissue will yield approximately 100 follicular units. [6] The yield will be less in dark skinned races whose follicular unit density is slightly lower [4]. The density will decrease in

subsequent sessions and will be even less if all, or part, of the first donor scar is incorporated into the next incision. It is important to adjust the size of the strip accordingly.

### **Local Anesthesia**

Local anesthesia is administered with a ring-block consisting of 60% lidocaine 0.5%, and 40% bupivacaine 0.025% with epinephrine 1:200,000 added to this mixture. Lidocaine is used for its safety and quick onset. Marcaine is used to increase the duration of anesthesia, but in smaller quantities to limit its potential cardiac toxicity. [26] Epinephrine increases the anesthetic duration while decreasing its toxicity and providing some hemostasis. Its short-lived vasoconstrictive properties limit its usefulness in long procedures. [27] Sodium bicarbonate 8.4%, 1:20 is added to bring the acidic pH of the epinephrine containing solution closer to 7.4, to lessen its sting. [28]

In the donor area, the anesthetic solution is injected into the deep subcutaneous fat layer, approximately 1 cm below the lower portion of the clipped area and extending several centimeters past it on either side. On the forehead, the anesthesia must be injected into the superficial dermis as well as the subcutaneous space to insure its effectiveness. It is important to avoid injecting anesthetic into the muscle, as epinephrine will cause vasodilatation (due to the action on  $\beta_2$ -receptors), quickly dissipating the local effects of the anesthetic and increasing its toxicity. [29]

After the area is anesthetized, additional tumescent anesthesia is administered by injecting larger quantities of a more dilute solution of lidocaine (0.17%) and epinephrine (1:600,000) into the mid-fat to indurate the area. The tumescence serves to: 1) increase the distance from the follicles (residing in the upper fat) to the nerves and larger blood vessels (lying just above the fascia), 2) increase the rigidity of the donor area (that helps to decrease follicular transection during the harvest), 4) decrease bleeding, 5) produce more uniform anesthesia and 6) reduce the total amount of anesthetic required.

### **Single Strip Harvesting**

When possible, the donor hair should be harvested as a single strip to minimize follicular transection. This can be accomplished with two parallel #10 blades set on a handle to cut the body of the strip, and then one blade used free-hand to taper the ends (we use the Rassman handle that angles the blades at 30° so that they are parallel to the emergent hair). Alternatively, the entire strip can be removed with an elongated free-hand ellipse [1]. In a patient with average scalp laxity, we generally harvest a donor strip that is 1 cm wide in the first session. It is important to plan the width of donor strip so that there is little or no tension on closure. (Figure 6)

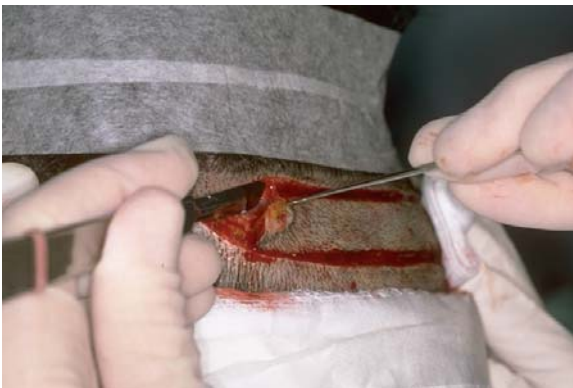

Figure 6. Single strip harvesting showing dissection in the subcutaneous plane using a #10 blade after the edges have been cut with two parallel blades on a Rassman handle.

An advantage of the free-hand method is that it allows the angle of the blade to be adjusted as each edge is cut. This technique, however, makes it harder to keep the width uniform; a prerequisite for predictable graft yields. Cutting the second edge also becomes more problematic since the tumescence is lost after the first incision and the tissue becomes more mobile.

As mentioned, the ideal location for the donor incision is in the mid-portion of the permanent zone that lies, in most people, at the level of the external occipital protuberance and the superior nuchal line. The muscles of the neck insert into the inferior portion of this ridge, so an incision below this anatomic landmark will be affected by the underlying muscle movement. A stretched scar in this location is extremely difficult to repair and re-excision risks an even wider defect. The main problems of harvesting hair too high on the posterior scalp are lack of permanence of the transplanted hair (since it may be subject to androgenic change) and future visibility of the scar with further hair loss.

In subsequent procedures, the new incision can incorporate all, or part, of the old scar or a totally new area can be accessed. The argument for a single incision is that in this method, the hair is always harvested from the mid-portion of the donor zone where the shaft has the widest diameter (producing the most fullness), the density is the greatest (necessitating the smallest incision) and the hair will have the greatest likelihood of being permanent. Those in favor of multiple incisions point out that the hair yield will be greater if the old scar is avoided and feel that there is a smaller risk of a widened scar. This multiple strip technique, however, often necessitates making incisions at the outer margins of the permanent zones.

### Donor Closure

The donor wound can be closed with a variety of suture materials and techniques. [30, 31] We prefer closing the donor wound with a running 5-0 suture made of the absorbable material poliglecaprone 25 [32]. Absorbable sutures can be placed very close to the wound edges (1.5 mm) without the concern that they become buried. Placing sutures close to the wound edge minimizes entrapment and destruction of follicles, particularly if there is significant post-op edema that increased tension on the closure. To further limit damage to follicles, the suture loops should be spaced approximately 4.5 mm apart and the stitch should be advanced on the surface of the skin to minimize the amount of suture in contact with the follicles. (Figure 7, 8)

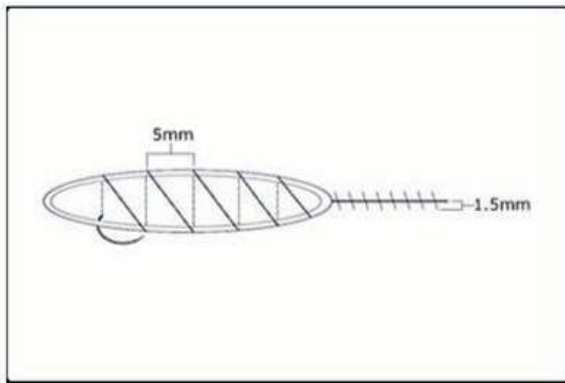


Figure 7. Schematic of suturing technique. The heavy, diagonal line represents suture on the skin surface. The light, vertical line represents suture advanced in the sub-cutaneous space.

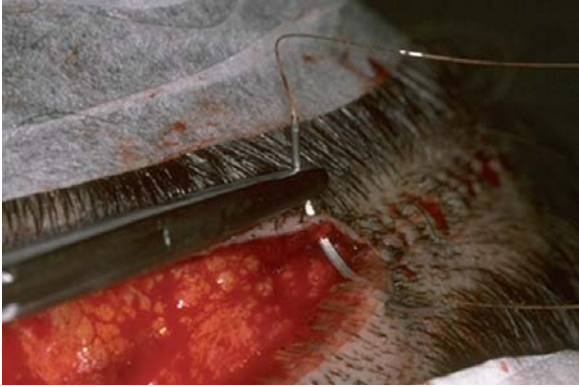


Figure 8. Suturing technique showing suture placement within 1.5mm of wound edge.

Possibly the most common closure is a running stitch using with nylon or polypropylene. These sutures can be used with or without interrupted subcutaneous sutures. The advantage of using subcutaneous sutures in this instance is that it allows the cutaneous stitches to be placed loosely and removed early, minimizing follicular damage.

Staples are useful in hair transplantation because they have virtually no tissue reactivity; however, they make apposition of wound edges difficult. They are also uncomfortable and not tolerated well by the patient. We have found that staples, more often than sutures, result in a stretched scar, due to the difficulty in closely opposing the wound edges and are more likely to leave a scar that is visibly linear. For these reasons we prefer absorbable sutures, although staples may be particularly useful in patients with high density and very loose scalps. [32]

### **Follicular Unit Extraction**

Individual follicular units can be harvested directly from the donor area, without the need for a linear incision, through a technique called Follicular Unit Extraction (FUE). In this procedure, a 1-mm punch is used to make a small circular incision around the upper part of the follicular unit, which is then extracted from the scalp. [14, 15]

Because FUE does not leave a linear scar, it is appropriate for patients who want to wear their hair very short. The procedure is also useful in patients who have healed poorly from traditional harvesting or who have a very tight scalp. Possibly the most important application of this technique is to camouflage a widened linear donor scar from a prior hair transplant procedure.

Patients differ significantly with respect to the ease in which the units can be extracted from the scalp, with extraction in some patients producing unacceptable levels of transection. Not being able to have three or more persons working in parallel, as with microscopic dissection, is another disadvantage of this technique.

FUE's main limitation is that it is less efficient in harvesting hair than follicular unit transplantation. In FUE, the defects remain open to heal by secondary intention and this causes significant scarring in the donor area. Although not clinically apparent, the scarring distorts follicular units adjacent to the harvested sites and makes subsequent sessions more difficult. In FUE, since a significant amount of intervening hair is left behind, a much larger region must be accessed to harvest the necessary amount of donor hair (compared to FUT). This forces the surgeon to eventually harvest hair from the inferior and superior margins of the traditional donor area and risks the hair being non-permanent.

All patients considering FUE should be tested for the ease of extraction (the FOX Test)<sup>2</sup> so that those who show significant degrees of transection can be identified in advance as non-candidates. Patients undergoing follicular unit transplantation should also be tested for follicular

unit extraction at the time of surgery, in the event FUE may be useful in a future session. One such use might be the camouflage of the linear scar after the patient's final FUT procedure.

### **Graft Dissection**

In single-strip harvesting, the excised donor strip is first divided, under stereo-microscopic control, into thin sections taking care to avoid transection of follicles or dividing follicular units. This process, called "slivering" is generally performed in one of two ways [33]. In the first, the larger strip is cut into very thin sections measuring only one follicular unit (1-mm) wide. In the second method, slightly wider sections (2-2.5 mm) are generated from the strip. These authors prefer the second method as we feel this technique makes it easier to keep the follicular units intact and generates a higher hair per follicular unit yield.

In either method, the strip is oriented on a water-soaked tongue-depressor blade with the hair pointing away from the dissector and the convex surface of the strip facing upward. One end of the strip is held with rat-toothed forceps by the person performing the slivering and the other end by an assistant to stabilize the strip. Some doctors obviate the need for a second person by pinning the free end of the strip to the dissecting board. The slivering is carried out using a #10 blade on a #3 blade handle. The dissector begins to cut through the width of the strip, guiding the blade between follicular units and slivering in a one-directional fillet-like movement from the epidermal side to the subcutaneous surface. A back-and-forth sawing motion will cause unnecessary damage to the follicles (Figure 9).

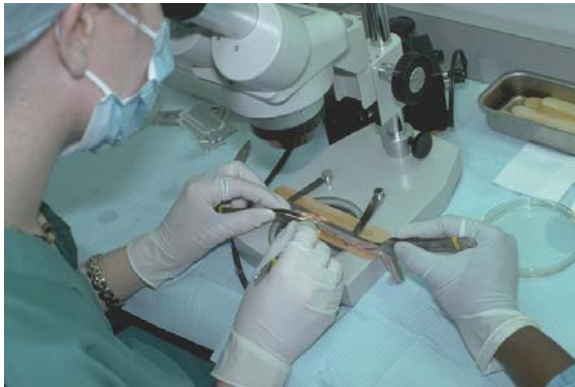

Figure 9. A donor strip is divided into thin sections in a process called "slivering." In slivering, the scalpel blade passes around follicular units as it cuts through the strip to avoid damage to the follicular structures and to keep the units intact. The free end of the strip is stabilized by an assistant.

Once the strip is divided into either 1-mm or 2-2.5mm slivers, the slivers are placed on their sides, stabilized with straight jeweler's forceps, and then dissected under the stereo-microscope into individual one- to four-hair follicular units (Figure 10, 11).

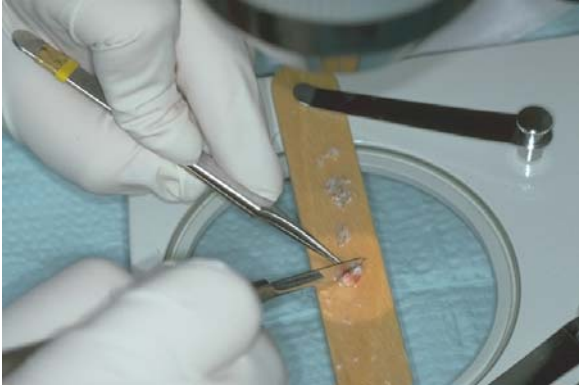


Figure 10. The slivers are dissected into individual follicular units.



Figure 11. One, two, three and four-hair follicular units.

As the follicular units are isolated, they are sorted according to the number of hairs they contain, and placed into Ringer's lactate filled Petri dishes set on ice blocks. When the several hundred grafts have been dissected, they are put into plastic specimen containers and refrigerated. All slivers and dissected follicular units should be bathed, at all times, in chilled Ringer's lactate. It is convenient to keep 10-cc syringes containing Ringer's lactate by each cutting surface for this purpose.

### **Creating Recipient Sites**

In follicular unit transplantation, the tools used to create recipient sites should not remove tissue, i.e. one should not use a punch or trephine, as this causes unnecessary destruction of the recipient area. The most important factor in determining which instrument to use is the diameter of the wound they create. A number of other factors, including the shape of the tip (spear or lancet) and whether they are solid core or hollow, have some impact on the surgery [34]. Common hypodermic needles are used by many practitioners. Although a discussion of the different types of instruments is beyond the scope of this writing, as a general guide; the equivalent of 20-g needles can be used for one-hair follicular units, 19-g needles for two-hair and thin 3-hair follicular units, and 18-g needles for three- and four-hair follicular units. In special situations, such as using individual hair for eyebrow restoration, finer needles may be appropriate. In patients of African descent with very kinky hair, one hair units will often require at least a 19-g needle and 2-hair grafts an 18g needle.

Although it is best to keep recipient sites small to minimize wounding of the recipient area, this should not be at the expense of the grafts. None of the recipient sites produced by hypodermic needles of 18-gauge diameters, or less, will produce a visible scar, so one should not use a recipient site so small that the graft must be forcibly inserted. One must also balance the advantage of keeping follicular unit grafts "chubby" to preserve telogen follicles and create more insulation for the



individual follicles (to prevent mechanical injury and desiccation) with the desire to make sites very small so that the grafts may be more densely packed.

There are two schools of thought with regard to making the recipient sites and inserting the grafts; pre-making the sites and the “stick and place method.” Pre-making all the recipient sites prior to graft insertion allows the physician to design the transplant and concentrate on angling and distribution without having to worry about the handling of grafts or their subsequent popping as additional sites are made. The actual creation of sites initiates coagulation so that when the grafts are placed there is little bleeding and no need for additional epinephrine. This allows for maximum visibility in the placing phase of the procedure. [35] The problem of matching the number of sites to the number of grafts can be solved by making mathematical projections of the anticipated number of grafts while the dissection is still in progress.

In the stick and place method, the grafts are inserted as the sites are made. [33] In this technique, the needle can actually be used as a shoehorn facilitating the insertion of the grafts. The advantage of this method is that it eliminates the problem of leaving sites unfilled and avoids the risk of placing two grafts in one site (“piggybacking”). On the other hand, it increases the risk of popping (since a new site is made next to a site containing a graft), it forces the staff to focus on the technical aspects of graft insertion at the same time they must concentrate on design elements (such as angling and distribution) and it leaves many of the aesthetic decisions in the hands of the technicians performing the stick and place, rather than the physician.

## **POSTOPERATIVE CARE**

After the grafts have been inserted, the scalp should be cleaned with distilled water to remove any residual blood. It is best to avoid using peroxide (even diluted) once the grafts have been placed. A final check is made to settle any grafts that are elevated. An antibiotic is applied to the sutures and a head-band type pressure dressing is placed over the donor area. The transplanted area is covered with a surgeon’s cap. Patients are given oral sedatives and pain medication, but if they have taken them during the procedure they are not permitted to drive home after the surgery.

Because the donor area is closed with absorbable sutures, patients do not need to return to the office for their removal; however, patients that live close to the office are seen a week after their procedure. Patients are seen again 8-12 months post-op to discuss their results and the possibility of additional surgery.

Patients are instructed to shampoo every three hours the day following surgery and twice daily for the next week. The purpose of the frequent showering the day following the procedure is to minimize crusting. Once the crusts adhere to the hair shaft they will be difficult to remove and may pose a cosmetic problem for several weeks. They also make the transplanted grafts less secure. The reason is that, although hair will dissociate from the transplanted grafts around 4 days post-op, crusts that have adhered to the epidermal surface of the grafts can cause them to dislodge if they are picked, or scratched, for up to 8 days following the procedure.

Patients are advised to avoid exercises that flex the neck and stretch the sutured donor wound. The length of time a patient needs to be careful depends upon the tension at closure and the length of the incision. Since polycapton 25 absorbable sutures lose their tensile strength in about three weeks, care should be taken for at least 4-6 weeks post-op. Photo-protection is advised for three months following the procedure and patient are instructed to avoid alcohol for a week and smoking for at least two weeks following surgery. If the patient chooses to continue Minoxidil after the procedure, it may be resumed in one to two weeks, as long as it doesn’t cause scalp irritation.



## AESTHETIC ISSUES

### The Frontal Hairline and Other Transition zones

Determining the position of the hairline and the importance of considering the vertex transition point in the long-term plan have been discussed in the section “Planning the Restoration.” The transplanted hairline must be restored to a position appropriate for a mature adult since, in contrast to one’s original hairline, it will not change its position or shape over time. In a mature adult, the mid-portion of the frontal hairline is approximately one finger-breadth (1.5-2 cm) above the brow crease. [2, 4]

Temple recession is more variable in the normal adult hairline so there is significant flexibility in designing this area. As a general rule, if a patient wants to wear his hair combed straight back, a hairline with more temporal recession will give a denser, fuller look. With side-to-side grooming, a broad hairline will look fuller. (Figures 12 and 13).

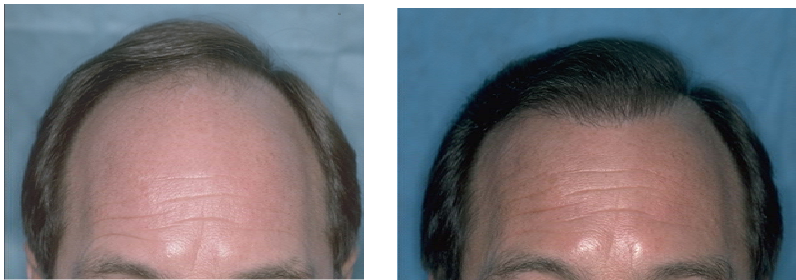


Figure 12. A) Before and B) After, in a patient who combs his hair back. High density was achieved in two sessions by keeping the frontal area relatively narrow.




Figure 13. A) Before and B) After, in a patient who combs his hair from left to right. High density was achieved in two sessions by taking advantage of side-to-side layering.

The key to producing a natural hairline is to create an irregular saw-tooth, or zigzag pattern, at the leading edge. It is more common to error by making the hair line too uniform than by making it too irregular. Besides being irregular, a hairline should also be slightly asymmetric. The transplant will look most natural if one side is shaped, and positioned, slightly different than the other. As a very general rule in choosing which side to make lower, it is often best to make the part side slight lower than the contra lateral side. Particular attention should be paid to facial asymmetry as this will often influence the position of the hairline.

Transition zones must be created wherever the edge of the transplanted area is visible. This occurs at the frontal hairline, in the crown, and in the part area on the sides of the scalp. In a typical transplant, approximately 200-250 one-hair follicular units are used for the front edge of the hairline. This is immediately followed by two-hair follicular unit grafts. The three- and four-hair units are concentrated in the forelock area, but should extend lateral and posterior in patients with higher density. In all locations, one- and two-hair follicular units should be placed peripheral to the larger grafts to insure a soft, natural appearance.

## Hair Direction

Particular attention should be paid to the angle of the recipient sites, since this will determine the ultimate direction that the hair will grow. Hair should be placed into the scalp at the angle it originally grew, not in the direction that it is to be groomed. In general, hair anterior to the vertex transition point should point forward, with the angle of the hair (with respect to the surface the scalp) becoming more acute as one approaches the anterior hairline. At the frontal hairline, the emergent hair is essentially horizontal to the ground (regardless of the slope of the forehead). The direction of hair in the frontal hairline continues to point forward until it approaches the temples where it abruptly changes to a downward anterior and then, at the apex of the temples, to a downward posterior direction. (Figure 14).

Two common mistakes are to transplant the hair radially at the hairline, rather than forward and to follow the direction of a lick or swirl that would otherwise disappear as the patient continued to bald.

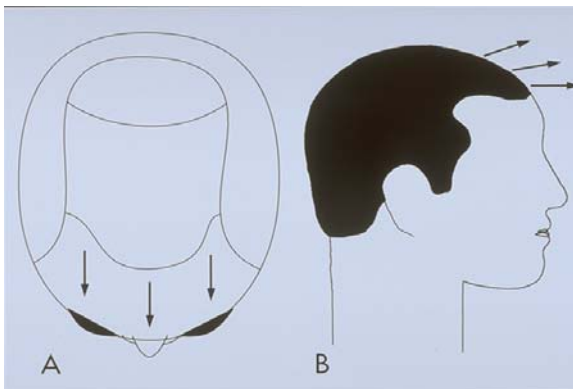


Figure 14. A. Hair should point forward from one fronto-temporal angle to the other. B. At the frontal hairline, the angle of the emergent hair is parallel to the ground.

Hair should point forward until it reaches the vertex transition point, the area in the posterior aspect of the scalp where the horizontal and vertical planes meet. At this point, the hair changes direction from a predominantly anterior to a radial direction, forming the crown whorl. This point is important in that it represents a natural stopping point for the transplant when the donor reserves are limited. [20, 21]

## Distribution

The area of the scalp subject to androgenetic alopecia can be divided into three regions: 1) the frontal hairline and frontal scalp, 2) the top or mid-scalp and 3) the vertex or crown. The vertex transition point separates the top of the scalp from the crown. [20] (Figure 5.) Since the frontal area of the scalp provides the greatest cosmetic impact, this area should have the greatest hair density. This can be accomplished by placing recipient sites in this area closer together (forward weighting). [4] Greater density can also be achieved by placing larger follicular units, i.e. those containing 3- and 4 hairs, in the forward/central part of the scalp (the forelock region). The larger units should not be used at the hairline, so that this zone will remain soft and natural, and they should not be evenly distributed across the scalp, as this will produce a diffuse rather than patterned look. The density should gradually decrease towards the crown. Figure 15 illustrates the overlapping distribution of forward weighting and the forelock zone of central density created by larger follicular unit grafts. [8]




Figure 15. The area of forward weighting, created by placing recipient sites closer together, is indicated by the darkened semi-circle. The zone of central density, created by using larger follicular unit grafts, is indicated by the dark egg-shaped region.

Most patients have enough donor hair to allow the surgeon to extend the transplant to the vertex transition point. As mentioned, this is a natural stopping point since, even if the crown continues to enlarge, transplants performed to this point will maintain a natural appearance, even without additional surgery. Transplants should be extended past the vertex transition point into the crown only when the doctor is relatively certain that there will be an adequate donor supply to create a swirl and follow the hair loss laterally if the balding progresses. The indications for transplanting the crown depend upon a number of additional factors and are detailed in reference 3.

Although the transplanted hair direction should not be based upon the way a person intends to groom his or her hair, there are other aspects of transplant design that should be influenced by hair styling preferences, if this is known in advance of the procedure. The degree of temple recession has already been mentioned. Another decision is graft weighting.

In general, the grafts should be forward weighted in the anterior-posterior direction, and symmetrically distributed from left to right. However if a patient is relatively certain that they will comb their hair to the side, or diagonally backwards, then hair may be weighted on the part side to give the appearance of greater fullness. This may be accomplished by creating recipient sites more closely together on the part side, by placing larger follicular units in this area, or by doing both. When using larger follicular units, it is important to still create a soft transition zone of one and two-hair units at the visible edge of the part.

It is difficult for patients, particularly those who are extensively bald, to know how they will comb their hair after the transplant. Because of this, it is best to transplant the first session in a symmetrical pattern. However, once the session has grown in, if they are relatively certain that they will continue to groom their hair in one specific way, subsequent sessions can be weighted to one side for greater fullness. Transplanting the first session symmetrically will help insure that there are no gaps in the distribution and that the weighting will not be at the expense of a natural look. (Figure 16).




Figure 16. Side weighting. The figure on the left, illustrates a gradual diagonal side-weighting of the larger grafts on the part-side (darkest area). The figure on the right shows side-weighting in the extreme where hair is concentrated at the frontal hairline and part-side. The remainder of the scalp has scattered follicular units called “tacking hairs” as they are used to hold down the hair from the frontal hairline and part side combed back over this area. [8]

### Regular vs. Dense Packing

It is generally accepted that transplanting up to 25 follicular units per  $\text{cm}^2$  will not impede their growth. Although there are few well controlled studies addressing the issue, many practitioners feel that “dense packing,” as defined by densities above 25 follicular unit/ $\text{cm}^2$  grafts, may risk graft survival when performed in large sessions and in certain patients. Until there are good scientific studies to clarify this issue, it is probably prudent to consider the following:

1. There is probably significant patient-to-patient variability in the ability to support grafts that are densely packed.
2. Significant solar damage, which alters the cutaneous vasculature, is a relative contraindication to dense packing.
3. Densely packed grafts are more difficult to place and have a greater risk of popping than more generously spaced grafts.
4. Dense packing should be considered when the majority of follicular unit grafts can fit into recipient site wounds no greater than those made with the equivalent of a 19-g hypodermic needle.
5. Dense packing is often performed by trimming grafts very closely and breaking up naturally occurring 4- and sometimes 3-hair follicular units.
6. The additional density achieved with very dense packing may come at the expense of graft survival.

One should consider that the average non-balding scalp has 100 follicular units per  $\text{cm}^2$  and that approximately 50% may be lost before there is any noticeable thinning. It would be wasteful, therefore, for more than 50% to be replaced – especially since transplants are always performed in the face of a limited donor supply. If the larger three- and four-hair units are placed in select areas, more than 25% of the initial density can be achieved in one pass of 25 follicular unit/ $\text{cm}^2$ . With two procedures this density can be achieved in many patients.<sup>8</sup>

Some physicians advocate a “one-pass” procedure to achieve the final density in one treatment session. [34] Although this may be appropriate for some patients, the increased incidence of graft popping, desiccation, insertion injury and possible vascular compromise, may lead to poor growth. For very bald patients, very dense packing may not permit coverage of an entire bald area unless very large numbers of grafts are used. Until good scientific studies demonstrate that dense packing in very large sessions will allow optimal growth in the majority of patients, covering the entire bald area with moderate density and then increasing density in a subsequent session may be a more judicious strategy, as this allows a natural distribution to be

created in the first procedure and it avoids the potential risks associated with very dense packing or extremely large sessions.

### **Coronal (horizontal) vs. Sagittal (vertical) Incisions**

Follicular units emerge from the scalp in either a bundle or in a linear array. When in a linear configuration, the orientation is generally in a coronal (horizontal) plane, allowing the follicular units to shingle and provide more coverage than if they were sagittal or random. It has been argued that during a hair transplant there is less scar contraction with a coronal incision compared to a sagittal one. This would allow follicular units to remain linear after they have been transplanted and provide the rationale for using coronally angled grafting (CAG) to best approximate the way hair grows in nature. [36]

The main advantage of CAG is that it would provide a fuller look to the transplant compared to traditional (sagittal) incisions. Another advantage is that grafts may be positioned at a more acute angle with the surface of the scalp and there may be less tendency of the growing hair to elevate in the vertical plane. This is particularly important at the temple/sideburn area where the hair lies very flat to the scalp surface. It is also felt by some practitioners that CAG exhibits less popping and that the wounds cause less damage to the vascular bed.

Doctors using sagittally angled grafts (SAG) feel that the pre-made vertical recipient sites are easier to see and that grafts are easier to place in these sites, minimizing injury to the follicular unit grafts. This may be particularly relevant in areas where there are significant amounts of hair present and the surgeon does not have the luxury of shaving the scalp before the procedure. It has also been pointed out that coronal incisions (which cross Langer's lines) potentially cause more damage to collagen and the cutaneous vasculature, than sagittal incisions. An additional concern is that, although there is possibly more hair elevation with sagittal than coronal incisions, there is less lateral (radial) splay of hair when the former is used. As with minimizing lift, minimizing lateral splay is also an issue of significant cosmetic importance. Finally, if one considers that many follicular units are not linear and that many linear units may indeed contract during the healing process and lose their linear orientation, CAG may offer only a theoretical advantage. [36-38]

At the time of this writing, there is no consensus on which method is best and if the differences are even significant for most patients, although there is a general trend towards CAG. As with many techniques used in hair restoration, the advantage of one over the other may ultimately depend upon the particular patient, a particular transplant session, or the skills and preferences of a particular surgeon. A number of researchers are currently examining these issues; however, regardless of the outcome, considering the rotational orientation of follicular unit graft adds an important new dimension to follicular unit transplantation. (Figures 17 and 18)

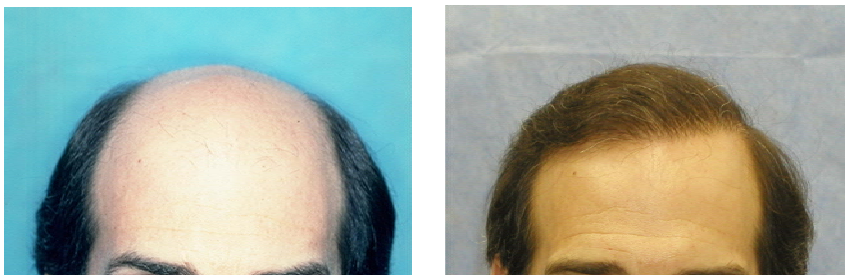


Figure 17. A) Before and B) After three sessions in a Norwood Class 6/7 patient with straight, medium-fine, dark hair and light skin. Sagittal slits were used in this patient.



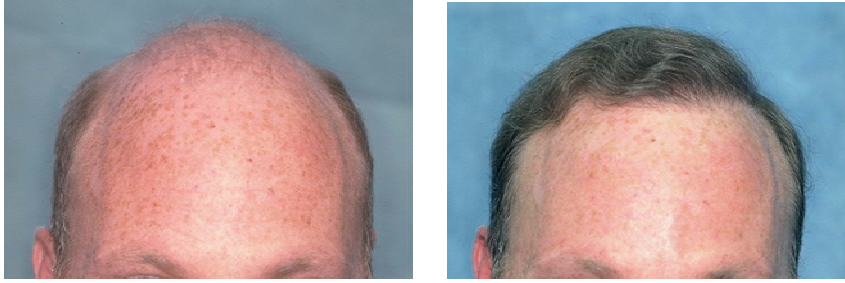


Figure 18. A) Before and B) After two sessions in a Norwood Class 6/7 patient with slightly wavy fine, blond hair and light skin. Note how recipient site factors caused the patient's original wave to return. Sagittal slits were used in this patient.

## PROBLEMS AND COMPLICATIONS

The use of large numbers of very small grafts, particularly follicular units, that became popular in the latter half of the 1990's, eliminated many of the problems encountered with the older plug procedures. With "modern" hair restoration techniques, however, problems still remain. These problems can be grouped into one of four broad categories; those caused by: 1) poor patient selection, 2) poor aesthetic judgment, 3) improper handling of grafts, and 4) wide donor scars. These issues have been discussed in the body of this paper so just a few points will be emphasized.

### Poor Patient Selection

Probably the most common error in hair transplantation is poor patient selection, particularly operating on patients who are too young. Since the goal of a young person is to restore his adolescent hairline, transplanting a patient who is too young, almost invariably leads to creating a hairline that is too low and/or too broad. And since a low, broad hairline is also associated with normal density, as the person ages (and his total hair volume decreases) re-distributing hair through the hair transplantation process will not be able to make the person's surgery look natural long-term. An attempt to provide coverage to a Norwood Class 6 or 7 patient, who has a permanent low, broad hairline, will result in a diffusely thin, non-patterned, look.

If a person younger than 23-25 is transplanted, it is important to place the hairline in a mature position (i.e. at least 1.5cm above the upper brow crease), create significant temple recession, and be reasonable certain that the patient does not have diffuse unpatterned alopecia (DUPA), i.e. that he has a stable permanent zone with no significant miniaturization. Since this design will rarely satisfy the younger patient, and since the stability of the donor area can rarely be known for certain at this age, the other alternative, waiting until the patient is more mature before undergoing surgery, is usually the more appropriate route.

It had been felt by some that the new, more effective hair loss medications, such as finasteride, will allow the surgeon to be more aggressive in operating on a younger patient. It is the opinion of these authors that the real value of these medications in the younger patient lies in their ability to postpone, rather than expedite, the decision to have surgery.

### Poor Aesthetic Judgment

One of the most common aesthetic mistakes is to place grafts radially along the frontal hairline, rather than in a forward direction. Unfortunately, grafts placed in the wrong direction (as well as those placed too low in the hairline) must be removed, since camouflage with additional hair will not correct the problem. The most satisfactory treatment in these cases is often laser hair removal since, with the advent of micrografting and follicular unit transplantation,

the grafts are often too small and too numerous to be individually excised and re-used. This results in wasted time and expense for the patient and, of course, the unnecessary loss of donor hair. The issue will be discussed in the section Corrective Procedures.

Another common error is to transplant the crown in a young person, or in a person who is just starting to thin in the vertex and who may become extensively bald. The procedure often accelerates hair loss in this area and commits the surgeon to performing multiple, small procedures to follow the expanding crown. This can leave the patient's donor reserves in short supply to address the frontal hairline, front and top part of the scalp, as the balding extends to these cosmetically more important areas.

### **Poor growth**

The nuances of graft handling are beyond the scope of this writing, nevertheless, improper handling of grafts is a major cause of poor growth and the reason that particular aesthetic goals are often not met. There are certain key points to consider if one is to have maximum graft survival. These are:

1. Grafts are subject to injury from the moment they leave the donor area until they are totally secure in the recipient scalp (up to 8 days post-op).
2. The staff must be continually supervised to insure that optimal graft handling is maintained through the entire procedure.
3. Damage to grafts can be caused by mechanical injury (transection during dissection or crush injury from improper use of forceps during placing), dehydration, chemical solutions (such as concentrated hydrogen peroxide), heat (from the OR lights or dissecting microscope) and hypoxia (from keeping the grafts out of the body too long. [11, 12]
4. Of the various forms of injury, desiccation is the most damaging and can place the grafts at greater risk of other forms of injury. [11]

### **Wide donor scars**

With the use of smaller grafts, having a pluggy look is no longer a major concern for patients and the fear of having a widened donor scar has come to the forefront. Although legitimate, this concern has been exacerbated by the frequent scarring that occurred from the older techniques, by inexperienced doctors harvesting donor strips that are too large (in an attempt to perform megasessions), by those hoping to exploit the fear of linear donor scars to promote non-surgical methods or follicular unit extraction, and by a complication being occasionally broadcast over the internet.

As with progress in the recipient area, achieved through the use of follicular units, there has been significant progress in our understanding of how to keep donor scars thin. These include:

1. Noting a history of stretched scars from other procedures
2. Carefully assessing scalp laxity to judge the width of the donor incision
3. limiting the width donor incision to 1.0-1.2 cm. for most patients to insure a low tension closure
4. When appropriate, decreasing the donor width in subsequent procedures
5. Harvesting from the mid-portion of the permanent zone for the following reasons:
  - a. the muscle movements of the neck will be transferred to low incisions and increase the risk of stretch
  - b. the hair around high donor incisions may not be permanent and may expose the scar
  - c. the hair removed in a high donor incision transplanted into the donor area may be lost over time

6. Using tumescent anesthesia to keep the donor incision superficial, i.e. in mid fat, so that it is below the follicles but above the fascia and major neurovascular bundles.
7. Waiting at least 6-8 months between procedures to allow for the wound to be completely healed and some donor laxity to return

Complications encountered in hair transplantation are infrequent. They include some of the problems seen with other minor out-patient surgical procedures such as: syncope from vaso-vagal reactions; anxiety, palpitations and hypertension from the epinephrine in the local anesthetic; hypotension from epinephrine-beta blocker interactions; post-op bleeding from improper suturing or coagulopathies; bacterial infections from intra-operative or post-op contamination; and a thickened donor scar from poor suturing techniques or factors intrinsic to a particular patient. If the local anesthetic is administered improperly, or in too high a dose, lidocaine toxicity can result. Rarely a patient may have an allergic reaction to the anesthetic or other medications administered during the procedure.

There are a number of problems that are more specific to hair transplantation. Post-op facial edema, that begins at the hairline and then settles into the bridge of the nose, is so common that it should be considered an intrinsic part of the procedure. Fortunately, it is generally mild and resolves within a week. There is some evidence that systemic corticosteroids can decrease the severity of the swelling.

Persistent numbness or paresthesias in the occipital scalp, which were once a common problem in hair transplantation, have been virtually eliminated by the use of tumescent anesthesia, as this helps to confine the depth of the donor incision to the subcutaneous space. Interestingly, the incidence of post-op hiccups, a complication attributed to injury of cervical nerves C2-C4, indirectly stimulating the vagus or diaphragmatic nerves, has also markedly diminished with the use of tumescence and more superficial donor incisions.

A sterile folliculitis not uncommonly occurs from 1-4 months post-procedure, as the new hair attempts to negotiate its way to the scalp surface, but gets trapped in the epidermal overgrowth at the follicular orifice. These lesions usually subside spontaneously without treatment. Occasionally they will become secondarily infected and require antibiotics or form a cyst that needs to be incised and drained.

Hair texture changes most likely result from the trauma associated with graft dissection and placement. It is less common with meticulously performed follicular unit transplantation and, in contrast to the permanent texture changes seen in large graft transplants, it is almost always transient. Skin texture changes are almost never seen in follicular unit transplantation if the recipient wound are kept to the equivalent of a 19- or 20-gauge needle at the hairline and an 18-gauge site overall.

Hair loss in the donor area can occasionally result from an excessively tight wound closure, particularly when the tension is increased by significant post-op edema. Hair loss in the immediate vicinity of the incision is more common. This can be caused by the entrapment of hair follicles within wide suture bites or by an inflammatory reaction to the suture material.

Some degree of hair loss in the recipient area, in the vicinity of the transplant, is so common that it, like post-op edema, should be considered an intrinsic part of the procedure. The mechanism is felt to be telogen effluvium, however, when miniaturized hair is shed, it often will not return, giving the appearance of a progression of the hair loss. Finasteride may offer some protection against this process, but this has not been proven. The physician should anticipate hair loss by avoiding performing a transplant too early. When the procedure is undertaken the surgeon should transplant enough hair to compensate for any potential loss. The important point is that the patient should be made aware of this aspect of a hair transplant and be told that, even in a perfectly executed procedure, at least some small degree of hair loss is the rule, rather than the exception.



## CORRECTIVE PROCEDURES

Traditionally, hair transplant surgeons have attempted to improve the appearance of larger grafts by placing a zone of smaller grafts in front of them. This had been an integral part of the doctor's strategy, when he/she used large grafts in the central scalp for density and smaller grafts around the perimeter for naturalness. Often, however, the end result was still unnatural. As an extension of the original thinking, additional sessions of small grafts were added to the initial ones in the hope of further improving the appearance of the larger grafts. (Figure 19)

A major shift in the approach to these patients came from the realization that camouflage alone is rarely adequate for restoring a natural appearance, particularly if the original grafts were too large, too far forward on the hairline, or pointing in the wrong direction. In these situations, only partial or complete excision of the original grafts would correct the problem. In fact, when the grafts are in the wrong position or direction, rather than just too large, their complete removal is generally the best option. [39, 40]

Grafts can be removed by either excising them, through punch or linear excision, or by removing the hair alone, via laser hair removal or electrolysis. When making a decision regarding the best way to remove the grafts, one should consider the quality of the underlying skin, as well as the actual hair in the grafts. If the underlying skin appears normal, then removing the hair alone may be the best choice.

One must also decide before hand where to place the hair that will be obtained from the grafts. If that patient wants to completely reverse the transplant, rather than repair existing grafts, and move forward with additional transplants after the correction, one should consider placing the hair back into the donor area.

If the patient wishes to proceed with further hair transplant procedures, the hair that is obtained from the plugs should be placed in an area that requires additional density (such as the central forelock area), but this hair should not be placed at the frontal hairline, since the hair obtained from plugs can be more wiry than hair taken from virgin scalp. If the patient has little, or no, donor reserves, then even the hair derived from the grafts should be used in the cosmetically most important areas, i.e. the hairline.

When the grafts have been placed close together, are in multiple rows, or are very large, multiple graft excision sessions are often needed. The surgeon should wait a minimum of eight weeks between these sessions to give time for the area to heal and to allow for the identification of any missed or transected follicles that might regrow. When possible, it is best to complete all the repair sessions requiring graft excision before additional donor hair is used, so that the graft excisions will not be encumbered by the additional hair. By waiting for the repairs to be complete, the doctor can easily visualize where to place the remaining donor hair and may have the option of using some of the additional hair to cover surface irregularities that have been uncovered by the graft excisions. (Figure 20)

A detailed discussion of repair work may be found in references 39 and 40. The following are key points to consider when performing corrective procedures:

1. Although it is more time consuming, patients will get a better cosmetic result if the grafts are sutured closed than if they are left to heal by secondary intention.
2. Grafts that are too large can be partially removed as long as they are in the central scalp and pointing in the proper direction.
3. Grafts that are in the wrong position, or pointing in the wrong direction, should be completely removed.
4. Punch excision, although more time consuming, usually gives a better cosmetic result than a linear excision.

5. For micrografts and follicular units that are pointing in the wrong direction, or that have been placed too far forward, laser hair removal is generally the best option.
6. It is best to complete the removal phase of the repair before additional hair is taken from the donor area.

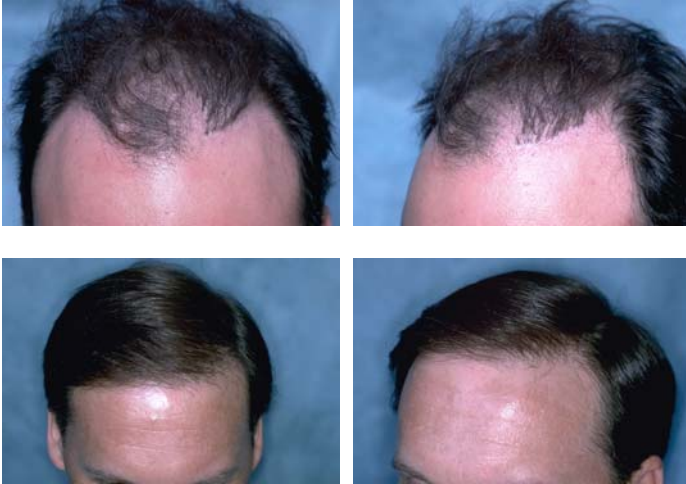

Figure 19. A,B). Before views of a patient treated with rows of grafts placed in his temples. These grafts became visible as his hairline receded. C,D) The patient was treated with just one session of follicular unit transplantation as the larger grafts were far enough behind the transplanted hairline to be camouflaged.

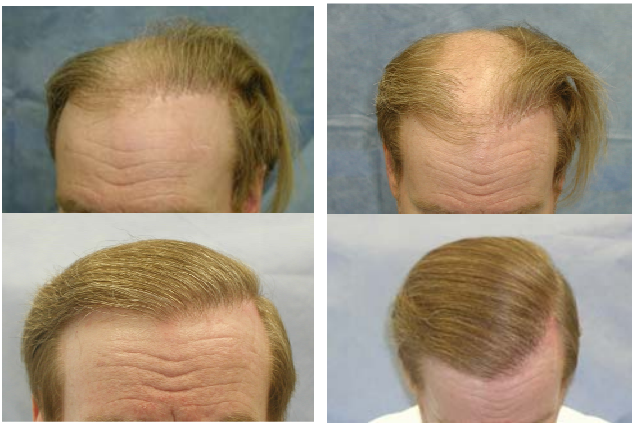

Figure 20. A,B) Before views of a patient with a rim of plugs, central baldness and a markedly depleted donor supply. C,D) Four corrective procedures were performed to remove the large grafts and redistribute them as individual follicular units in the front part of his scalp. In the fifth procedure, 1,184 follicular units were transplanted from the donor area into the front and mid-portion of his scalp. Although he still relies on a comb-over to add fullness to the top part of his scalp, note the natural appearance of the restoration.

## SUMMARY

The recognition that the follicular unit is a discrete, anatomic and physiologic entity, and that preserving it through stereo-microscopic dissection is the best way to ensure the naturalness of

the restoration, has brought hair transplantation into the twenty-first century. Issues yet to be resolved include: determining the maximum density and number of grafts that can be safely used in a single session, finding the ideal rotational orientation of the grafts, deciding whether it is preferable to pre-make recipient sites or immediately place grafts into sites as they are made, and defining the precise role of follicular unit extraction.

Regardless of how these issues are ultimately resolved, the essence of providing the best care for patients will continue to rest on proper patient selection, establishing realistic expectations, and using non-surgical management for young persons who are just starting to thin. When hair transplantation is indicated, it should be accomplished in larger, rather than small sessions and be performed by a team experienced in the dissection and handling of the thousands of tiny follicular unit grafts needed to accomplish the restoration. Only with meticulous attention to every aesthetic and technical detail can the best cosmetic result be assured.

## REFERENCES

1. Limmer BL. Elliptical donor stereoscopically assisted micrografting as an approach to further refinement in hair transplantation. *Dermatol Surg* 1994; 20:789-793.
2. Bernstein RM, Rassman WR, Szaniawski W, Halperin A. Follicular transplantation. *Intl J Aesthetic Rest Surg* 1995; 3:119-132.
3. Bernstein RM, Rassman WR: Follicular transplantation: patient evaluation and surgical planning. *Dermatol Surg* 1997; 23:771-784.
4. Bernstein RM, Rassman WR: The aesthetics of follicular transplantation. *Dermatol Surg* 1997; 23:785-799.
5. Headington JT. Transverse microscopic anatomy of the human scalp. *Arch Dermatol* 1984; 120:449-456.
6. Bernstein RM, Rassman WR: The logic of follicular unit transplantation. *Dermatologic Clinics* 1999; 17(2):277-295.
7. Windam C. Beyond the Comb-Over. *The Wall Street Journal*, New York, NY, November 11, 2003. pg D1.
8. Unger WP, Shapiro R. *Hair transplantation*. New York: Marcel Dekker; 2004.
9. Seager D: Binocular stereoscopic dissecting microscopes: should we use them? *Hair Transplant Forum International* 6(4):2-5, 1996.
10. Beehner ML. A study comparing growth of "intact" FUs and "non-intact" grafts. *Hair Transplant Forum International* 13(6):461-2, 2003.
11. Gandelman M, et al: Light and electron microscopic analysis of controlled injury to follicular unit grafts. *Dermatol Surgery* 2000; 26(1): 31.
12. Greco J: The H-factor in micrografting procedures. *Hair Transplant Forum International* 6(4):8-9, 1996.
13. Limmer B: Thoughts on the extensive micrografting technique in hair transplantation. *Hair Transplant Forum International* 6(5):16-18, 1996.
14. Rassman WR, Bernstein RM, McClellan R, Jones R, et al. Follicular Unit Extraction: Minimally invasive surgery for hair transplantation. *Dermatol Surg* 2002; 28(8): 720-7.
15. Bernstein RM, Rassman WR, Anderson KW: Follicular Unit Extraction Megasessions: Evolution of a technique. *Hair Transplant Forum International* 2004; 14(3): 97-99.
16. Kuster W, Happle R. The inheritance of common baldness: two B or not two B? *J Am Acad Dermatol* 1984;11:921-926.
17. Norwood OT. Male pattern baldness: classification and incidence. *So Med J* 1975; 68:1359-1365.

18. Bernstein RM, Follicular Unit Hair Transplantation. In: Robinson JK, Hanke CW, Siegel DM, Sengelmann RD, editors: *Surgery of the Skin*, Chapter 34. Elsevier Mosby Inc., London UK. 2005.
19. Bernstein RM, Rassman WR: The scalp laxity paradox. *Hair Transplant Forum Intl* 2002; 12(1):9-10.
20. Beehner M. Nomenclature proposal for the zones and landmarks of the balding scalp. *Dermatol Surg* 2001; 27:375-380.
21. Bernstein RM, Rassman WR, Seager D, Shapiro R, et al. Standardizing the classification and description of follicular unit transplantation and mini-micrografting techniques. *Dermatol Surg* 1998; 24:957-963.
22. Smith JB, Fenske NA. Cutaneous manifestations and consequences of smoking. *J Am Acad Dermatol* 1996; 34:717-32.
23. Haas A, Grekin R. Antibiotic prophylaxis in dermatologic surgery. *J Am Acad Dermatol* 1995; 32:155-176.
24. Bernstein RM, Rassman WR. Dissecting microscope versus magnifying loupes with transillumination in the preparation of follicular unit grafts: a bilateral controlled study. *Dermatol Surg* 1998; 24:875-880.
25. Limmer BL. Micrograft survival. In: Stough DB, Haber, RS, eds. *Hair replacement: surgical and medical*. St. Louis: Mosby; 1996:147-149.
26. McCaughey W. Adverse effects of local anesthetics. *Drug Safety* 1992; 7:178-189.
27. Bernstein RM, Rassman WR: Hemostasis with minimal epinephrine. *Hair Transplant Forum Intl* 1999; 9(5):153.
28. Skidmore R, Patterson J, Tomsick R. Local anesthetics. *Dermatol Surg* 1996; 22:511-522.
29. Weiner N, Norepinephrine, epinephrine, and the sympathomimetic amines. In: Goodman AG, Gillman LS. *The pharmacological basis of therapeutics*, 7th ed. Chapter 8:151-159. New York: Macmillan; 1985.
30. Bennett RG: Selection of wound closure materials. *J Am Acad Dermatol* 1988; 18:619-637.
31. Moy RL, Waldman B, Hein DW: A review of sutures and suturing techniques. *J Dermatol Surg Oncol* 1992; 18:785-795.
32. Bernstein RM, Rassman WR, Rashid N: A new suture for hair transplantation: Poliglecaprone 25. *Dermatol Surg* 2001; 27(1):5-11.
33. Seager, D. The 'one-pass hair transplant' – a six-year perspective. *Hair Transplant Forum Intl* 2003; 12(1):176-178, 194-196.
34. Arnold J: Mini-blades and a mini-blade handle for hair transplantation. *Am J Cosm Surg* 1997; 14(2):195-200.
35. Bernstein RM, Rassman WR: Limiting epinephrine in large hair transplant sessions. *Hair Transplant Forum Intl* 2000; 10(2):39-42.
36. Hasson V. The coronal incision recipient site Unger WP, Shapiro R. *Hair transplantation*. New York: Marcel Dekker; 2004. 898-900.
37. Martinick JH. Coronal (CAG) versus sagittal angled grafting (SAG). *Hair Transplant Forum Intl* 2003; 13(2):293-296.
38. Parsley WM. Coronal vs. sagittal recipient incisions. *ESHRS Journal*; Winter 2003:14-15.
39. Bernstein RM, Rassman WR, Rashid N, Shiell R: The art of repair in surgical hair restoration – part I: basic repair strategies. *Dermatol Surg* 2002; 28(9):783-794.
40. Bernstein RM, Rassman WR, Rashid N, Shiell R: The art of repair in surgical hair restoration – part II: the tactics of repair. *Dermatol Surg* 2002; 28(10):873-893.