Surgery of the Skin; Chapter 34. 2005
Editors: Robinson JK, Hanke CW, Siegel DM, Sengelmann RD.

Follicular Unit Hair Transplantation

Robert M Bernstein MD

Summary Box

- Follicular Unit Transplantation (FUT) is a method of hair restoration surgery that relocates hair in follicular units, its naturally occurring groupings. The small size of the units allows for tremendous versatility in their placement, the creation of hair patterns closely mimicking nature and transplant procedures large enough that a full restoration can often be achieved in just two sessions.
- Since FUT requires large numbers of grafts, it is important to accurately assess patients' donor reserves in the initial planning. Densitometry enables the physician to estimate the total number of movable hairs, the size of the individual follicular units and the degree of miniaturization in both the donor and recipient areas. Scalp laxity assessment is also crucial to the surgical planning.
- Great care should be taken to screen for patients who are too young or whose hair loss may be diffuse and involve the donor area.
- Identifying androgenetic alopecia often proves more difficult in women as other medical conditions must be considered. Options for medical treatment options are more limited in female patients and many experience diffuse hair loss, a relative contra-indication to surgery.
- Determining the right size and location of the donor strip prevents problems such as widened and/or visible scars. The follicular units obtained from donor strips are delicate structures. Careful dissection, gentle handling and adequate hydration are essential to their survival.
- In order to dissect and place the thousands of grafts often required in FUT, the surgical team must be proficient in stereo-microscopic dissection and inserting techniques – skills that can take a year or more to develop.
- Follicular Unit Transplantation requires an astute aesthetic sense for optimal hairline design, correct angling and distribution of grafts and the establishment of a master plan that anticipates further hair loss and is consistent with the long-term goals of the patient.

INTRODUCTION

Within the past decade, Follicular Unit Transplantation (FUT) has transformed hair transplantation from a cosmetically unpredictable procedure to one that can produce consistently natural results. The key to its effectiveness lies in the fact that scalp hair tends to grow in tiny bundles, called "follicular units," rather than individually.[1] By working with these naturally occurring units, instead of larger or smaller grafts, FUT creates as natural a look as possible while minimizing the transplant wound size and accelerating post-operative healing. A recently developed refinement, Follicular Unit Extraction, promises to eliminate, for select candidates, the

procedure's most invasive aspect: the surgical removal of a strip of tissue from which the units are harvested.[2]

Follicular units are made up of one to four terminal hairs, one to two vellus hairs, their associated sebaceous glands, neurovascular plexus, an erector pilorum muscle, and a circumferential band of adventitial collagen, the perifolliculum.[3] The tendency of scalp hair to grow in this way, rather than in single hairs, can be most easily demonstrated by clipping the hair to approximately 1 mm in length and then viewing it with a densitometer at x 30 magnification in a 10-mm field.[4] What this also reveals is that these compact units are surrounded by significant amounts of non-hair-bearing scalp.[5] Including this extra skin in the dissection -- as do transplants with larger grafts, such as plugs and minigrafts -- requires a larger recipient wound, as well as risking visible scarring in the skin around the grafts and distortions of the growing hair.

In FUT, these naturally occurring units are used exclusively. The FUT procedure takes advantage of the anatomic proximity of the hairs within each unit to: 1) keep the recipient site wound size to a minimum, 2) virtually eliminate any skin surface change in the recipient area, 3) facilitate post-op healing, 4) enable grafts to be placed very close together and 5) permit large numbers of grafts to be safely transplanted in a single session (because of the small recipient wound size).[1,6] The ability to insert up to four hairs in a tiny recipient site is especially valuable cosmetically and has been instrumental in eliminating the see-through quality of micrografting. In the end, what this means is that the transplanted hair will look natural, as long as the transplant surgeon makes the right aesthetic decisions about graft placement, angling and distribution.[7,8]

The higher precision of FUT as compared to mini-micrografting is especially obvious when methods of harvesting the grafts are compared. In FUT, once a strip of donor tissue has been removed, follicular units are taken out intact through careful stereo-microscopic dissection, avoiding injury to the follicles.[9,10,11] The grafts in mini-micrografting, on the other hand, may or may not correspond to individual follicular units. They are cut from the donor strip according to the number of hairs they contain (optimally one to six, but often more) and/or the size of tissue required to fit into a given recipient site, a process known as 'grafts cut-to-size'. Often the dissection is performed without magnification, and it is also common for the donor tissue to be removed with a multi-bladed knife, rather than as a single strip, causing significant destruction of follicles. Because the grafts may be too large to fit into a slit incision, an excision (where recipient tissue is removed, such as with a small punch) is sometimes needed. In contrast, the recipient sites used for FUT always consist of small incisional slits.

In a new procedure called Follicular Unit Extraction (FUE)[2], the need for a donor strip is eliminated entirely. In this procedure, individual follicular units are removed (extracted) directly from the donor area through a small circular incision with, or without, micro-dissection. Although this procedure obviates the need for a linear strip, it has limitations, particularly in the inability to efficiently utilize all the tissue in the mid-portion of the permanent zone. As of this writing, most surgeons performing FUE have used it for select patients only. A brief description of this procedure will be included in the section on the donor harvest under Techniques [cross ref].

The purpose of this chapter is to elaborate on the basic technical skills and aesthetic judgments involved in FUT. It should be taken as a framework for physicians interested in learning the procedure, not an exhaustive review of the various surgical techniques used in FUT or of other hair restoration methods. The chapter will not cover mini-micrografting, which is still widely practiced,[12] the combining of large and small grafts,[13] laser hair transplantation,[14,15] scalp reductions,[16,17] scalp lifts,[18] or flaps.[19] These procedures have been detailed in many excellent publications, as well as in two comprehensive textbooks.[20,12]

When learning FUT, the importance of hands-on experience and beginning with small sessions until ones' skills develop cannot be overemphasized. Having a well-trained team of assistants is also important to a successful outcome, particularly for those procedures involving a large number of grafts.

Although simple in concept, FUT has many nuances and complexities. Those wishing to perform FUT in their clinical practice are encouraged to join the International Society of Hair Restoration Surgery (ISHRS) and attend its annual meeting, subscribe to Hair Transplant Forum International (the trade publication for hair restoration surgeons), and follow relevant medical literature (particularly Dermatologic Surgery). Although it is not an accredited board, certification by the American Board of Hair Restoration Surgery (ABHRS) indicates a basic competency in the field and requires three years of clinical experience and passing both oral and written examinations. The process of preparing for ABHRS certification is a worthwhile endeavor and recommended for those serious about surgical hair restoration.

Historical Vignette

Reports of successful hair transplants appeared as early as 1930 in Japanese literature, beginning with Sasagawa's hair-shaft insertion procedure[21] and then Okuda's success in pioneering 2- to 4-mm punches for the treatment of various alopecias of the scalp, eyebrows and moustache. Okuda made the important observation that using smaller punches in the recipient area improved cosmetic results.[22]

By 1943, Tamura had treated 137 cases of non-androgenetic alopecia of various etiologies using techniques very similar to modern-day hair transplantation.[23] For instance, he harvested donor grafts by making an elliptical incision that was sutured closed, prepared recipient sites with a thick needle, stored grafts in physiologic saline, and observed post-operative telogen effluvium. Most significantly, Tamura demonstrated that single-hair grafting resulted in growth practically indistinguishable from naturally grown hair--and much more natural-looking than transplants using larger grafts. But it took several decades before Western surgeons would apply Tamura's insights to their hair restoration procedures.

The first hair transplant in the United States was performed by Dr. Norman Orentreich in 1952 with grafts measuring 6 to 8 mm in diameter,[24] significantly larger than those of either Tamura or Okuda. At first, incredulous editors rejected Orentreich's work, not believing that hair transplantation was even possible. He finally found a publisher in 1959, in the Annals of the New York Academy of Science. The paper laid out the concept of "donor dominance"--the idea that grafts continue to show the characteristics of the donor site after they have been transplanted to a new site. This remains the basic tenet of all hair transplantation surgery. Yet while donor dominance insured that transplanted hair could grow, it did not guarantee that the results would look natural.

Not until 40 years later would transplants in the United States start to produce consistently natural-looking results and promise predictable cosmetic improvements in most patients. It was a slow evolution, but the large grafts used throughout the sixties and seventies eventually gave way to minigrafts in the eighties[4] and mini-micrografting in the early nineties.[25] The stage was then set for Follicular Unit Transplantation. First appearing in the medical literature in 1995[1] it quickly emerged as the standard in hair restoration--supplanting mini-micrografting in the treatment of androgenetic alopecia and rendering other well-established procedures such as scalp reductions, scalp lifts and flaps virtually obsolete.

So swift was FUT's ascent that the two standard textbooks on surgical hair restoration, published in 1995[20] and 1996,[12] as well as the most comprehensive text on trichology, published in 1997,[26] make not one mention of the terms "follicular unit" or "Follicular Unit Transplantation." At the 1996 meeting of the International Society of Hair Restoration Surgeons, three seven-minute presentations on the procedure were given; but at the 2002 meeting, FUT was the subject of entire seminars and workshops and suffused every aspect of the weeklong gathering.

The follicular unit was first defined by Headington in his landmark 1984 paper "Transverse Microscopic Anatomy of the Human Scalp."[3] Follicular Unit Transplantation had its origins in the microscopic dissection techniques of Dr. Limmer in 1988 that was described in his paper "Elliptical Donor Stereoscopically Assisted Micrografting as an Approach to Further Refinement in Hair Transplantation" in 1994.[9] The term "follicular unit" was introduced into the hair transplant literature by Bernstein and Rassman in 1995. The conceptual framework for FUT was mapped out by these authors in the publication "Follicular Transplantation"[1] and in the paired articles, "Follicular Transplantation: Patient Evaluation and Surgical Planning" and "The Aesthetics of Follicular Transplantation" (1997).[7,8]

The name "Follicular Unit Transplantation" was formalized by a group of hair restoration surgeons in a 1998 publication in Dermatologic Surgery.[10] In this paper, the procedure was precisely defined and included the two basic techniques, single-strip harvesting and stereo-microscopic dissection, as integral parts of the procedure. However, since follicular units can now be harvested directly from the donor area without the necessity of a strip incision (using Follicular Unit Extraction[2]) the original definition has become too restrictive.

The term Follicular Unit Transplantation should now be used to encompass all hair restoration procedures that utilize naturally occurring, individual follicular units exclusively in the surgery, regardless of how these units are harvested. The caveat, of course, is that the harvesting technique must always maintain the follicular unit's integrity.

PREOPERATIVE PREPARATION

Patient Evaluation and Surgical Planning

Diagnosis and Classification of Androgenetic Alopecia

The diagnosis of androgenetic alopecia in men is generally straightforward. It is made by observing a "patterned" distribution of hair loss and confirmed by the presence of miniaturized hairs in the areas of thinning. The diagnosis is supported by both the inexorable progression of the hair loss according to a recognizable pattern and a history of baldness in the family.[27] In women, the diagnosis is more complex, as the most common presentation, a diffuse pattern, can be mimicked by a host of non-androgenetic etiologies.

Miniaturization--the progressive diminution of the hair shaft's diameter and length in response to androgens--can be most readily observed with a densitometer,[12] a hand-held instrument that magnifies a small area of the scalp where the hair has been clipped to about 1 mm. One type, the Rassman densitometer,[4] magnifies by 30x in a visual field of $10mm^2$, making it easy to spot miniaturization and calculate hair density. (Figs 34.1-34.3)

When describing hair loss, particularly in the early phases, it is preferable to think in terms of changes in volume rather than density. Density is simply the number of hairs per unit area, whereas volume reflects both hair shaft diameter as well as the absolute numbers of hairs.[28] The earliest signs of hair loss, that of miniaturization, result in volume changes caused by the individual hair decreasing in size without a decrease in their number. Only in more advanced balding will the actual number of hairs start to decrease.[1]

The Norwood classification of male hair loss, published in 1975, remains the most widely used.[29] It defines two major patterns and several less common types (Fig. 34.4). In the regular

Fig. 34.1 Hair Densitometer.

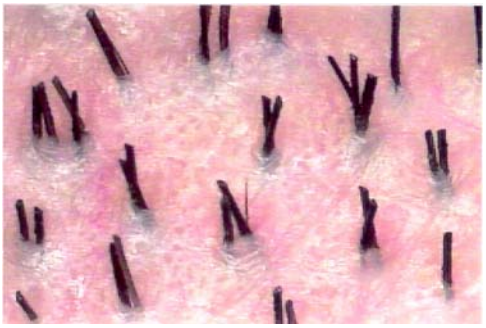
Fig. 34.2 Natural hair groupings as seen through a densitometer (magnification x 30).

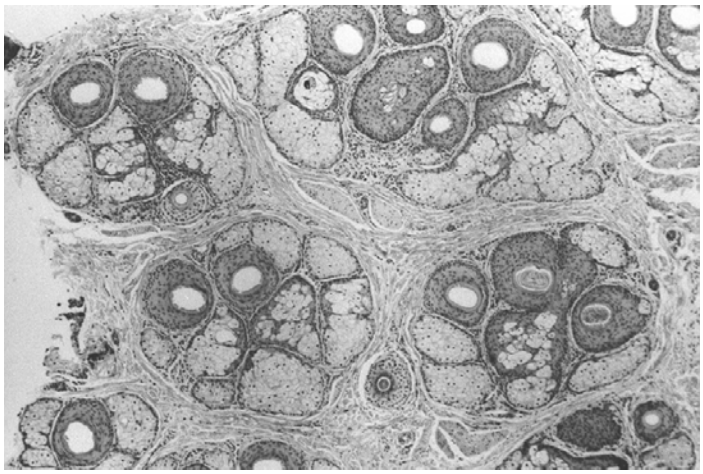
Fig. 34.3 Histological view of follicular units corresponding to the natural hair groups observed on the scalp surface. Transverse section taken at the level of sebaceous glands (hematoxylin and eosin, original magnification x 40).[6]

Norwood pattern, two areas of hair loss--a bitemporal recession and thinning crown--gradually enlarge and coalesce until the entire front, top and crown (vertex) of the scalp are bald. The less common pattern, Norwood Class A, is characterized by a distinctly anterior to posterior

progression usually resulting in baldness on the front and top of the scalp, but more limited loss in the crown. In both patterns, the sides and back tend to resist androgenetic changes, though the sides may exhibit significant thinning in senile alopecia.

Two other types of genetic hair loss not emphasized in the literature, Diffuse Patterned and Diffuse Unpatterned Alopecia, pose the greatest challenge both for diagnosis and patient management. A thorough familiarity with all of these patterns is essential for diagnosing androgenetic alopecia and planning FUT (Table 34.1).

Table 34.1 Classification of Androgenetic Alopecia

Norwood Classes
- Regular Norwood Classes I to VII
- Type A Variant (IIa to Va)

  Variations:
  - persistent frontal forelock
  - persistent frontal hairline

Diffuse Androgenic Alopecias
- Diffuse Patterned Alopecia (DPA)
- Diffuse Unpatterned Alopecia (DUPA)

Senile Alopecia

Diffuse Patterned Alopecia (DPA) is an androgenetic alopecia manifested as diffuse thinning in the front, top and vertex, with a stable permanent zone. In DPA, the entire top of the scalp gradually miniaturizes without passing through the typical Norwood stages. Diffuse Unpatterned Alopecia (DUPA) is also androgenetic but lacks a stable permanent zone and affects

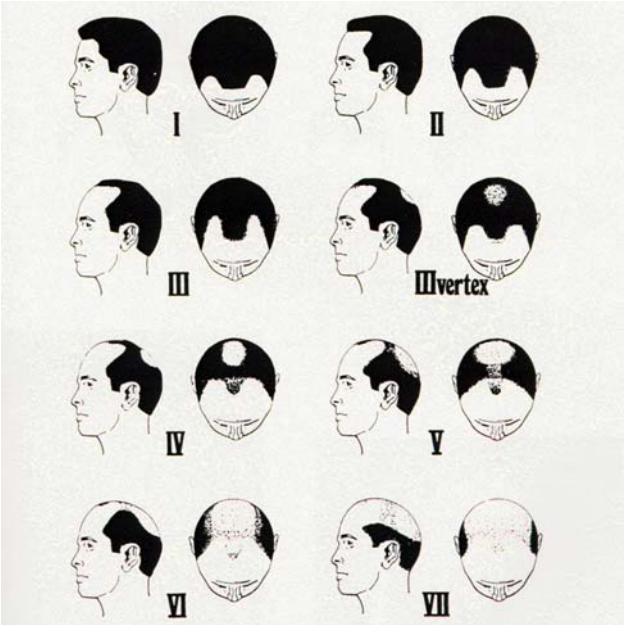

Fig. 34.4 Norwood Classification.[28]

men much less often than DPA. DUPA tends to advance faster than DPA and eventuate in a horseshoe pattern resembling the Norwood class VII. However, unlike the Norwood VII, the DUPA horseshoe can look almost transparent due to the low density of the back and sides. Differentiating between DPA and DUPA is very important because DPA patients often make good transplant candidates whereas DUPA patients almost never do, as they inevitably suffer extensive hair loss without a stable zone for harvesting.[7]

There are five early signs of DUPA:

- A rapid decrease in hair volume (as distinguished from density) and a change in hair texture at an early age, often in the teens.
- The maintenance of an adolescent hair pattern and persistent frontal hairline in spite of dramatic volume change.
- A see-through donor area, which is greatly accentuated when the hair is lifted up.
- Significant miniaturization of the donor area (>35%).
- A donor density $\leq$ 1.5 hairs/mm^2. (Densitometry's acute sensitivity in detecting early DUPA certainly justifies its routine use in the evaluation of hair loss.)

If a diagnosis of DUPA is even remotely suspected, any decisions regarding surgical hair restoration should be postponed. The possibility of missing a DUPA diagnosis is one of the most powerful arguments against performing hair transplantation at an early age.

Both DPA and DUPA occur in women; but, in contrast to men, DUPA proves far more common. As with men, female DUPA patients do not make good transplant candidates (except possibly when donor hair is used solely to soften the frontal edge of a wig). Indeed, the higher DUPA incidence in women explains why a smaller proportion of women than men qualify as transplant candidates. Interestingly, the most common classification used for women, the Ludwig Classification, does not differentiate between DPA and DUPA.[30]

It is important to emphasize that since a wide variety of medical conditions can produce diffuse hair loss, a non-androgenetic differential must be considered in all unpatterned alopecias. This is particularly relevant in evaluating women in whom unpatterned hair loss is the rule rather than exception (Table 34.2). The following laboratory tests are often useful when a non-androgenetic cause for diffuse hair loss is suspected: chemistry screen, complete blood count, serum iron, total ion-binding capacity, triiodothyronine, thyroxine, thyroid-stimulating hormone, antinuclear antibody and serologic test for syphilis.

Table 34.2 Non-Androgenetic Causes of Diffuse Hair Loss in Women

- Anemia
- Endocrine diseases (esp. thyroid)
- Connective tissue disease
- Obstetric/Gynecologic conditions (e.g. postpartum, polycystic ovarian disease)
- Weight loss (esp. crash diets)
- Emotional and physical stress (e.g. surgery, anesthesia)
- Medications: oral contraceptives, thyroid drugs, antihypertensives (esp. β-blockers), psychotropics, anticoagulants, antilipemics, gout therapy, prednisone, excessive Vitamin A or tryptophan use

---

In women, diffuse or patterned hair loss may be a sign of excessive androgen production. A further medical evaluation is indicated when the hair loss is associated with any of the following: cystic acne, irregular menses, hirsuitism, virilization, infertility or galactorrahea.

Serum levels of DHEA-Sulfate, androstenedione, total and free testosterone and prolactin levels can serve as a useful screen.[31]

When the diagnosis of androgenetic alopecia is uncertain, further diagnostic information can be gleaned from a hair-pull test for telogen effluvium, a potassium hydroxide mount and culture for fungus, a microscopic examination of the hair bulb and shaft, and a scalp biopsy (sectioned horizontally).[32] But a dermatologic consultation is warranted whenever the diagnosis of hair loss is unclear.

Who is a Candidate for Hair Transplantation?

In all cosmetic procedures, a successful outcome depends on proper patient selection (Table 34.3). In surgical hair restoration, proper timing is also crucial. The only reason for performing a transplant sooner rather than later is for its cosmetic benefit; there are no medical or surgical advantages to transplanting at an early age. The popular rationale that transplants should be performed at a young age so that "no one will notice" does not make sense: If there is nothing to notice after the transplant matures, why perform it in the first place? FUTs heal so quickly and the hair growth is so gradual that, once the short post-op period ends, the process is almost always undetectable.

Table 34.3. Patient Selection in the Surgical Treatment of Androgenetic Alopecia

Age: 23-25 years or older
Inadequate response to medication after one year
Significant hair loss: Norwood Class III or greater
Diffuse patterned alopecia (DUPA) has been ruled out
Non-androgenetic causes of hair loss have been ruled out*
No medical contraindications to surgery (e.g. drug sensitivities, keloids, connective tissue disease†)
Reasonable patient expectations

** Many non-androgenetic causes of hair loss can be treated with hair transplantation*
† Some are relative contraindications

Patients seeking hair transplantation while still in their early twenties invariably wish to have their adolescent hairline and original density restored. Since neither of these goals can be achieved surgically without compromising the patient's future appearance, the procedure should not be performed at his age. It should be explained that hair transplantation is a procedure that moves, rather than creates, new hair, so that it can never increase overall hair volume. And, in the face of decreasing total volume over time, the pattern of the transplanted hair must take into account this decreased total hair mass. In other words, patients who will have significant balding need to have built-in temporal recession and possibly a crown that is significantly thinner than the surrounding hair for the transplant to look natural over time. Unfortunately, neither of these is generally acceptable to a young man in his early twenties.

Another reason to postpone transplants for those under 25 or with only limited hair loss is to give medications--particularly finasteride--adequate time to work. Since patients may continue to show regrowth for up to two years after treatment is initiated, they should in general take finasteride at least this long before surgery is considered. It is inappropriate, therefore, to start

younger patients on finasteride and schedule surgery at the same time. Fortunately, finasteride works best in younger patients and especially those with large areas of miniaturized scalp rather than areas that are totally bald. On the other hand, for older patients who would be taking finasteride to maintain rather than regrow hair, and for those whose advanced state of hair loss makes results from finasteride unlikely, the medication may be prescribed concomitantly with surgery scheduling (see "Preoperative Preparation").

With the availability of finasteride, medication plays an increasingly important role in the management of androgenetic hair loss. Although the incidence is small (2%), the stigma of possible sexual side effects has turned many against this drug. Many also consider surgery a more conservative form of treatment than the potential lifetime use of a drug. Because of these concerns, and the often palpable desire of panicked patients to rush to surgery, the physician should take time to thoroughly discuss the pros and cons of medical therapy in all patients.

In the Norwood Classification, Class I represents a normal adolescent pattern and Class II a normal non-balding adult. Therefore, at minimum patients should qualify as Class III before transplants are contemplated. Early Class III patients will often benefit from medication alone, so this should be considered first. On the other end of the spectrum, extensive balding need not make a patient unsuitable for surgery, so long as the donor zone is stable (miniaturization <20%) and the patient's expectations are commensurate with his or her available donor supply. As long as the patient is in good health, there is no upper age limit. In fact, older patients tend to have the most reasonable expectations and often make the best candidates.

There are few absolute medical contraindications to surgical hair restoration, particularly since it is an outpatient procedure not requiring general anesthesia. Relative contraindications include: bleeding disorders, immunodeficiency, unstable arrhythmias, COPD, sensitivity to local anesthetics or adrenaline, a history of keloid formation or connective tissue disease and major psychiatric disorders. When in doubt about patients' medical condition, it is always best to get medical clearance from their primary physician. Patients should be able to tolerate being in the surgical chair a good part of the day; consequently, back and neck problems as well as claustrophobia can sometimes make the procedure problematic. Special care should be taken when evaluating patients with significant psychiatric problems, particularly depression; in such cases, a psychiatrist or psychologist should participate in the decision-making process.

Possibly the most difficult part of the consultation is managing patients' expectations. It is almost a cliché to say that they must have "reasonable expectations," but ensuring this is the essence of the evaluation. The surgeon cannot stress strongly enough that, since transplants move rather than create hair, the resulting density will be significantly less than in the original site. It is also important to emphasize that it is the patient's own hair, from the sides and back of his or her head, that will be transplanted. And the final result can be best described with reference to the texture, color, curl and other qualities of the patient's existing hair. But in addition to a thorough discussion, it is also helpful to provide prospective patients with printed material and photos and to make past patients available for them to meet.

Assessing the Patient's Donor Supply

The main factors in determining total donor reserves are donor density, scalp laxity and size of the donor area.

Donor Density

The number of follicular units in the mid-portion of the donor area of a normal Caucasian male who has not had surgery is approximately one per mm^2.[8] In the first procedure, therefore, the donor area should yield approximately one follicular graft per mm^2 of scalp, provided there is no significant

wastage during surgery. The average yield declines when longer strips are taken since density decreases towards the sides. In some individuals, density varies dramatically throughout the donor area, but this is the exception rather than the rule.

Since the number of follicular units per unit area stays relatively constant, donor density is an indication of the average number of hairs per graft. For example, if a patient has a density of two hairs per mm^2, the donor area will generally contain one follicular unit per mm^2 and the grafts will consist of a combination of one-, two- and three-hair units, with the average being two hairs per graft. With a density of 2.3 hairs per mm^2, there will still be one follicular unit per mm^2, so the same number of grafts will be harvested per unit donor area, but the grafts will have an average of 2.3 hairs per mm^2 and consist of a mix of fewer one-hair units and a larger percentage of three- and four-hair units.[8]

Follicular unit density varies according to race, thus the number of grafts obtained per unit area of donor tissue will also exhibit racial variability and must be accounted for in the surgical planning.[8]

If the scalp has been stretched from previous transplants, scalp reductions or scalp lifts, the follicular units will be spaced further apart, making it necessary to actually measure the density of follicular units to accurately estimate the number of grafts obtainable from the strip (as the density of follicular units will now be less than $1/mm^2$).

Donor scarring from previous surgeries will also significantly diminish the donor yield. All donor harvests, no matter how perfectly executed, entail some loss of hair. In addition, the angle of the hair surrounding the scar will be altered slightly, creating more transection in any subsequent harvest.

A person can lose a substantial amount of hair volume--either due to actual loss of hair or to miniaturization--before it becomes noticeable. When the hair is blonde or white, it takes longer for thinning to show, while it is evident sooner for those with black hair and white skin. For those with average density and average hair attributes, approximately half of the hair in the donor area may be moved without a significant change in appearance.

Scalp Laxity

Scalp laxity is an important factor in determining total available donor hair. In those with loose scalps, harvesting the donor strip merely removes some scalp redundancy while only slightly affecting density (hairs per mm^2). With tight scalps, however, each procedure stretches the skin, measurably decreasing density. The limitations of a tight scalp are usually not apparent in the initial surgery, but in subsequent procedures it can become much harder to perform a non-tension closure or, in the face of decreased density, to harvest a significant amount of hair. Therefore, the long-term goals of those with tight scalps must reflect a more limited donor supply.

At the same time, patients with very loose scalps tend to heal with widened scars and so often make poor candidates for procedures using a linear incision. Some, in fact, may have undiagnosed connective tissue disease.[33] Follicular unit extraction should be considered in cases of very loose and very tight scalps.[2]

Donor Dimensions

The mid-portion of the harvestable donor zone generally lies over the occipital protuberance and extends to within 3 cm of the temple hairline on either side. This distance is approximately 32-34 cm. Recession at the temples can signal extensive balding and portends a limited donor supply. The height of the permanent zone can vary markedly from person to person and should be carefully measured. Hair should be harvested only where it is stable, i.e. where it lacks significant miniaturization. An often overlooked sign is the “ascending” hairline, characterized by miniaturization in the lower margin of the permanent zone. Both receding temples and an

ascending posterior hairline indicate a shrinking donor zone and mandate conservative surgical planning.

Planning the First Hair Transplant Session

Ideally, the main goals of the first transplant session should be:

1. To establish the frontal hairline and frame the face.
2. To provide coverage to all bald areas of the scalp, from the frontal hairline back to the vertex transition point.[34]
3. To create sufficient density so that the results will look natural after one session, though additional sessions may be desired.[7]

These goals may not be achievable with a small or inexperienced surgical team, but should be the ultimate aim of those performing hair restoration surgery. In this author's opinion, there is little medical or aesthetic justification for performing the surgery in arbitrarily small sessions. It is preferable that each procedure cover the entire area of hair loss intended to be treated and be designed to "stand alone."[7, 8]

In an alternate approach to surgical planning, the objective is to achieve final density in a one-pass procedure by creating high density in smaller area and then transplanting another area in a subsequent session. This is accomplished in part by using very small recipient sites, limiting graft size to three hairs and using the stick-and-place method, in which grafts are inserted as soon as the recipient sites are made.[35]

As the number of grafts placed per unit area (density) rises, so too does the risk of vascular compromise that may result in sub-optimal graft growth. Technical problems of popping that may cause the grafts to become desiccated or that exposes the grafts to mechanical injury on reinsertion, also becomes more likely. Proper patient selection and technical expertise help avoid such problems, but the risks are increased nevertheless. It certainly behooves those with more limited experience to be conservative in this aspect of the procedure.

Because the blood supply to the scalp is extensively collateralized,[36] the risk of vascular compromise is related more to the density of grafts in a specific area and the size of the recipient wounds, than the absolute numbers of grafts placed. For this reason, the transplantation of a large number of grafts over a broad area does not seem to pose the same problems as producing very high densities. In addition, popping becomes less of a technical issue when the same number of grafts are placed over a larger area. However, transplanting large number of grafts (in "mega-sessions") poses its own challenges, such as increasing the time the grafts remain outside the body, requiring more staff, contributing to patient and staff fatigue, and creating organizational issues. As with dense-packing, the use of very large sessions should be reserved for only the most experienced surgical teams.

Though the amount of hair needed to cover the front and top of the patient's scalp will vary, an attempt should be made to achieve this coverage, if only lightly, in the first session. Crown coverage should not be a goal of the first session unless the patient has an above-average donor supply; if it is attempted in the first session, the patient's options will be more limited and the chances for an aesthetically balanced transplant may be permanently compromised.

Table 34.4 offers general guidelines as to the number of follicular units needed for the first hair transplant procedure.

Table 34.4 Number of Grafts in First Follicular Unit Transplant Session

Norwood Class	Follicular Units	Total Units with Crown

III	800-1000+	---
III Vertex	800-1000+	1100-1300+
IIIa	1300-1600+	---
IV	1100-1400+	1500-1800+
IVa	1700-2100+	---
V	1500-1800+	1900-2400+
Va	2000-2400+	---
VI	2000-2400+	2400+
VII	2000-2400+	---

Planning a Second Session

Timing of the Second Session

Transplanted hair sheds around two to six weeks after the procedure, and the first signs of new growth occur on average in approximately 10 weeks, though the onset can vary considerably, taking as long as four to six months or more. Hair gradually increases in both thickness and length, so that the initial growth is often not indicative of the final result. In less than 5% of patients, hair grows unabated after surgery, skipping the shedding phase.

One should generally wait 8-12 months to best appreciate the cosmetic impact of the procedure. During this time, the continued increase in the hair's diameter and length strikingly alters the patient's appearance. Once the hair reaches styling length, both the patient and physician can make aesthetic judgments about the weighting and balance of additional grafts.

It will also be advantageous to delay the second procedure to maximize the donor harvest. Although each procedure results in a potentially tighter scalp, some of the preoperative donor laxity returns in the months following the surgery. The major change will occur during the first month as the edema and inflammation subside. However, further loosening will occur as the scalp stretches over the next six to 12 months.

In the uncommon event of telogen effluvium occurring in the donor area, the telogen follicles may not be easily identifiable in the dissection. Since recovery in the donor area may take up to a year, it is essential that patients wait until complete regrowth has taken place before a second session is performed. In rare cases, if the closure is too tight, the effluvium may eventuate in permanent hair loss.

Goals for the Second Session

The main goals of the second session are:

1. To add density to areas transplanted in the first session.
2. To refine the hairline.
3. To follow the progression of the hair loss (if necessary).
4. To extend the transplant into the crown (when appropriate).

In general, most patients require two sessions to achieve adequate density. The hairline often can benefit from a little tweaking to make the leading edge softer and more irregular. Placing the hairline too low is a common mistake, but so is placing it too high, something often done with the intention of bringing it down on the second session, once the patient can see how it looks. It is better to get the hairline position right in the first session; lowering it later often leaves the leading edge too thin.

The decision regarding crown coverage is important because it is the least visible of the balding regions, but can potentially occupy a very large surface area, producing an almost inexhaustible demand upon the donor supply.

If extensive balding appears likely and the patient has a modest donor supply, the crown should be treated as an extension of the top, rather than an isolated region, to ensure that the patient will not be short of hair if the intervening bridge between the front and crown were to require additional grafts. Unless the patient's history, age and physical exam indicate limited balding, it is particularly important to avoid creating high density in the crown, as subsequent balding could leave an isolated island of hair. How much of the crown to cover is a critical decision; though the least visible of the balding regions, it can occupy a very large surface area, generating an almost inexhaustible demand upon the donor supply.

A useful alternative to covering the crown with transplanted hair is to halt the transplant at the vertex transition point.[34,37] The patient can then groom the hair back to conceal the non-transplanted area. This is recommended when direct crown coverage is not realistic or it is too early in the balding process to determine whether significant crown coverage will be possible in the future. Another advantage of sparing, or lightly covering, the crown is that donor reserves may be saved to address further diminution of the donor fringe.

Subsequent Transplant Sessions

The surgeon should make every attempt to accomplish the restoration in as few sessions as possible, rather than putting patients through an unnecessarily protracted course of multiple surgeries that can mar both their donor area and lifestyle. A second session is especially problematic for actively balding patients, therefore, when patients are experiencing an accelerated phase of hair loss, medical therapy should be encouraged and in general surgery should be postponed.

The number of grafts required to achieve patient satisfaction varies widely due to the great variability in hair characteristics. Moreover, since hair loss patterns form a continuum while the Norwood classes are discrete, even the transplant size necessary for each class can vary significantly. Table 34.5 shows the approximate number of follicular implants necessary for a complete restoration, without and with crown coverage.

Table 34.5 Total Number of Follicular Unit Grafts for a Complete Restoration

Norwood Class	Follicular Units	Total Units with Crown
III	900-1500	---
III Vertex	900-1500	1300-2000
IIIa	1400-2200	---
IV	1200-2000	1700-3000
IVa	1800-3600	---
V	1700-3000	2100-4000
Va	2400-4400	---
VI	2200-4600	3000-5600
VII	2200-4800	4000-6600

The Patient

Doctors commonly place patients on finasteride before surgery to minimize the chance of post-surgical effluvium. Although there are no scientific studies confirming that it is effective in doing this, it would seem that if the goal is to prevent post-surgical shedding, the medication should be

prescribed at least several months prior to the procedure. If, however, the intent is to postpone or obviate the need for surgery, then it should be taken for a minimum of one year.

Patients using topical minoxidil are advised to discontinue its use several days before surgery (because of its vasodilator properties) and wait until a week after the procedure before resuming (to avoid the irritating effects of the alcohol in the 2% solution or the propylene glycol in the 5% solution). Although we suggest minoxidil in combination with finasteride for patients with early hair loss, we generally do not recommend its use after a hair transplant, unless it is being used in an area other than that which was transplanted (such as the crown). We feel that minoxidil has little added value for the average post-transplant patient. We do, however, encourage the continued use of finasteride to help retard further balding. Those who do not plan to use minoxidil after surgery should discontinue it immediately, so that any of its beneficial effects may be reversed by the time of surgery.

Patients are advised to avoid products that are used to thicken the hair or stain the scalp for three days prior to the procedure, as these often take several days to wash out of the scalp completely. Their presence during surgery can decrease visibility and make placing more difficult. All hair systems should be removed prior to surgery and be replaced with, or converted to, a clip-on system. The front edge of the piece can be kept in place with a stiffening-rod without the need for glue or tape. However, any form of attachment at or near the frontal hairline risks dislodging grafts. Patients are encouraged to permanently discontinue the system after the procedure, but those who feel the need to use them until their hair grows in should wait at least five days post-op.

Systemic antibiotics are not indicated for clean surgical wounds in healthy patients, so their routine use in hair transplantation is not necessary; however, many doctors - perhaps the majority - do routinely use them. Because there are no specific guidelines for antibiotic prophylaxis in hair transplantation for patients with a history of endocarditis or mitral valve prolapse, the decision to use them must be based on the individual patient's risk factors. This topic is covered in an excellent review by Haas and Grekin.[38]

The other pre-op instructions are relatively straightforward and will depend to some degree on the preferences of the operating surgeon. Patients should be notified well in advance of the procedure date regarding the need to discontinue certain medications, stop smoking and abstain from alcohol prior to surgery. Table 34.6 is a summary of the main preoperative instructions.

Table 34.6 Preoperative Instructions

- Continue medications currently prescribed by your physician, particularly those for high blood pressure. Those on broad β-blockers (such as propranolol) should switch to select β-blockers, as the former may interact with epinephrine. This should be done under a doctor's supervision.
- Discontinue topical minoxidil and avoid products used to thicken the hair or stain the scalp three days prior to the procedure.
- In order to minimize bleeding, avoid the following prior to surgery: aspirin or other anti-inflammatory medications (one to two weeks), B or E vitamins (one week), or alcoholic beverages (three days). Do not drink coffee or any other caffeinated beverages on the day of your procedure as these substances will increase your sensitivity to medications such as adrenaline.

- Do not smoke tobacco products for at least 24 hours before your procedure and at least one to two weeks after. Smoking will slow down healing and heighten the chances of wound infection and scarring.
- The morning of your procedure, take a bath or shower and wash your hair thoroughly using a surgical scrub (contains 3% chloroxylenol). If possible, leave your hair long in the back and on the sides to cover the sutures.
- Wear clothes that do not need to be pulled on over your head; this will help keep your bandage in place and avoid any damage to your grafts immediately after surgery.
- Eat breakfast the morning of your procedure. If you are scheduled for surgery in the afternoon, have a light lunch before you arrive.
- Because you may be receiving medications during the procedure that can make you drowsy, you cannot drive home following the surgery. If you must drive or take public transportation, please let your doctor know ahead of time.

All patients undergoing hair transplantation should be treated with universal precautions. Although there is no consensus on the need to perform routine blood tests before the procedure, the following tests add an additional level of safety:

- complete blood count
- hepatitis B surface antigen and antibody
- hepatitis C antibody
- HIV screen

One should obtain medical clearance for HIV-positive patients to make sure that they are immunocompetent enough to withstand a potential series of procedures. With the hepatitis antigen-positive patient, there is concern about active disease and one should inform the patient's primary physician of any positive screening. Other tests, such as a platelet count and prothrombin and thromboplastin times are performed only if warranted by the history and physical.

The surgical consent form should be given to patients to read at their leisure well in advance of the procedure and should be signed before any medications that can cause drowsiness or impair judgment have been given. The exact time of signing should be indicated. The major elements of the consent form are listed in Table 34.7.

Table 34.7 Elements of the Consent Form for Hair Transplantation

- Nature of the procedure, with specific reference to its cosmetic nature
- Indications for surgery
- Risks: reactions to anesthetics, allergic reactions, sterile folliculitis, infection, cyst formation at graft site, scarring in donor area, hair loss related to the procedure, hair texture changes, failure of transplanted hair to grow, numbness, paresthesias, temporary swelling or bruising
- Benefits
- Alternatives
    - Doing nothing
    - Change hair styles (e.g. lightening or keeping hair very short)
    - Medical therapy
    - Another form of hair restoration surgery (e.g. mini-micrografting)
    - Wearing a hairpiece

- Results are not guaranteed
- Consent for photograph as part of the medical record
- Caution about driving under the influence of medication
- Statement that the above are understood and all questions have been answered
- Signature of the patient with date and time (prior to the administration of drugs), countersigned by the operating physician and witnessed by a staff member

---

The morning of the surgery, the patient should shower using a chlorhexadine surgical scrub as shampoo. Though it does not sterilize the scalp, the chlorhexadine binds to the stratum corneum, decreasing transient and pathogenic microorganisms and resident skin flora. Caution is advised, as it can be toxic to the middle ear and irritating to the eyes. After showering, the patient should dress in comfortable clothes and wear a button-down shirt.

THE OPERATING ROOM

Follicular Unit Transplantation is typically performed in an out-patient, office setting. The guidelines of care for office surgical facilities delineated by the American Academy of Dermatology should be reviewed before setting up facilities.[39,40] Though major complications occur only rarely, protocols should be in place to handle emergencies such as hypersensitivity reactions/anaphylaxis, stroke, seizures, arrhythmias, acute myocardial infarction and hypertensive crisis. At a minimum, specific arrangements should be made with a local Emergency Medical Services (EMS) facility to take care of distressed patients.[41]

The medical staff should be comfortable dealing with problems such as bleeding, syncope (with or without petit mal episodes) and anxiety reactions. The medical staff should be certified in cardiopulmonary resuscitation and at least some in advanced cardiac life support. The amount of in-office emergency equipment will depend on staff capabilities and training and proximity to an EMS unit. Basic equipment includes portable oxygen, an automated defribulator, IV setup and oral or nasopharyngeal airway.[41]

Because of the scalp's abundant vascular supply and relative resistance to infection, it is common practice for doctors' technique to be aseptic, rather than sterile. And since the scalp is not usually shaved and prepped, strict sterile technique is not practical. However, at least until the donor area is sutured closed, a sterile environment should be maintained. This issue is discussed in greater detail by Sebben and Davis.[42,43]

The single most important instrument for FUT is the dissecting stereo-microscope,[9,44] which is available with either a binocular view or with LCD screen. Each member of the surgical team performing the dissection should have one. Experienced teams generally require one staff member per 500 to 750 grafts (for graft dissection and placing), so that a typical 2000-graft procedure would necessitate three to four staff members in addition to the physician, though this will vary tremendously among practices. Less-experienced teams may require more people. The staff's other responsibilities as well as possible absenteeism must also be taken into account.

Regular operating-room tables are generally inadequate. Rather, the tables must be contoured and provide some lumbar support when patients are sitting. They also need to be low to the ground, with the seat not more than 56 cm from the floor, so the staff can work comfortably around the head while the patient is seated.

Equally important are comfortable working areas for the staff. Dissecting tables with a bull nose, rather than squared edge, are easier on their arms, and adjustable seating saves them from bending over to look into the microscopes (Fig. 34.5). The long duration of the surgery

makes meticulous attention to ergonomic issues all the more crucial.[45] Bright fluorescent ceiling lighting is preferable to surgical OR lights because it generates less heat. We use high-intensity surgical lights only for working on the donor area, as they can be angled to illuminate the posterior scalp of the seated patient.[46]

The Petri dishes containing grafts pending placement should be kept on a stable, wall-mounted surface to keep them from being inadvertently knocked over (Fig. 34.6). The typical operating room Mayo stand is not stable enough.[47] Normal saline is the most frequently used holding solution for grafts, but we prefer the more physiologic Lactated Ringer's. Limmer has shown a high survival rate for grafts kept in chilled saline up to eight hours.[48] More exotic solutions with potential graft-sustaining properties have been developed, but they are not widely used.[49,50]

Fig. 34.5 Dissecting stereo-microscopes on cutting table.

Fig. 34.6 Wall-mounted placing stand for ice blocks, grafts and instruments.[47]

Grafts should be refrigerated most of the time they are outside the body. Approximately one hour prior to placement, we remove a portion of the grafts from refrigeration and put them into Petri dishes that are resting on ice packs that maintain the Ringer's solution at 59^0C. This is set on a wall-mounted stand conveniently located at the head of the operating chair.

It is preferable to have all the dissection performed in the operating room. In addition, a small refrigerator used solely for graft storage should be located in each room. Performing all the dissection and storing the grafts in the same room eliminates the risk of inadvertently placing grafts in the wrong patient. Although obvious, this is particularly important in a busy practice where more than one person is being operated on per day. The minimum room size for a physician and five staff members to work comfortably is approximately 15.5 sq meters.

In advance of the procedure, it is helpful to set up complete surgical trays, including the local anesthetic mixtures predrawn into syringes. This serves a number of purposes: it makes it

easier to keep track of how much anesthetic is used in each part of the procedure, ensures that safe dose limits are not exceeded[51] and minimizes the risk of needle-stick injury, since the preparation takes place before the OR begins to bustle.

Local anesthesia is administered with a ring-block consisting of lidocaine, bupivacaine and epinephrine buffered with sodium bicarbonate. Lidocaine, the major component, is used for its safety and quick onset. Bupivacaine is added to increase the duration of anesthesia, but in smaller quantities to limit its potential cardiac toxicity.[52] Epinephrine increases the anesthetic duration while decreasing its toxicity and providing some hemostasis, though its vasoconstrictive action is relatively short-lived. Bicarbonate is added to bring the acidic pH of the epinephrine containing solution closer to 7.4, lessening its sting.[53] This is particularly useful for injections at the hairline, where the scalp tends to be most sensitive. Though mentioned elsewhere in this text, it is worth repeating that the combined use of epinephrine and broad β-blockers (e.g. propranolol) can result in potentially life-threatening reactions.[54]

The anesthetic solution used for a typical 2000-graft session is listed in Table 34.8. The anesthetic is drawn into 13 5-cc syringes then fitted with 27-g needles. The tumescent mixture consists of 3 10-cc syringes with 25-g needles. These quantities are preprinted on the operative report and circled as each syringe is used. If patients require additional anesthesia, they are reevaluated and then the medication drawn up and dose recorded.

TECHNIQUES

On arriving at the office, patients sign the consent form (which had been given to them well in advance). The surgical plan is reviewed and any last-minute questions answered. Next, density is checked to confirm the measurement taken at the initial consultation; if the number differs or it appears that density varies in the donor area, multiple measurements are taken. Scalp laxity is also reassessed and recorded on the operative report.

Patients proceed to change into a cotton surgical gown and have their picture taken with a digital camera against a light-blue background. Then the hairline and other important landmarks, such as the vertex transition point and crown swirl, are marked in Gentian violet and shown to the patient using two mirrors. If the patient approves of the hairline design, additional pictures are taken, this time of the marked scalp, usually from the front and aerial views. Three-quarter and close-up photos are sometimes taken to illustrate particular cosmetic issues. Occasionally pictures will be taken during and after the operation for teaching purposes. All photos are kept as part of patients' permanent medical record.

Typical patients are premedicated with diazepam 15 mg PO, Dicloxacillin 1000 mg PO (with a second dose of 500 mg six hours into the procedure) and an intramuscular injection of methylprednisolone 80 mg, i.e. 40 mg in each arm.

Donor Harvest

In preparation for the donor harvest, patients are seated upright on the operating table. The hair in the donor area--that covering the donor strip plus the 0.5 cm beyond its perimeter--is then cut to 1-2 mm using electric clippers (the extra 0.5 cm to facilitate suturing). The trimmings are thoroughly vacuumed away and the hair above the strip is held back with tape, fully exposing the donor area. A gauze headband is placed around the patients' head just below the clipped area and sterile drapes are taped to the headband.

In the first session, in a patient with average scalp laxity, we generally harvest a donor strip that is 1 cm wide. In calculating the length, we use the general rule of 100 follicular units per cm^2.[6] For example, if 1500 follicular unit grafts are planned, the strip would measure 18 cm in

length (15 cm + 3 cm for tapering). Africans and occasionally Asians will have a lower follicular unit density and a strip of this dimension will yield a lower number of follicular unit grafts. However, the length should not be increased; rather the session should be planned using fewer grafts.[8]

Local Anesthesia

A ring-block is established using a lidocaine/marcaine/adrenaline anesthetic mixture (Table 34.8). The anesthetic solution is injected into the deep subcutaneous fat layer approximately 1 cm below the lower portion of the clipped area and extending several centimeters past it on either side.

Approximately 0.75 cc of anesthesia are used per centimeter of donor area, so that a 25-cm-long incision would require slightly less than 20 cc of anesthetic solution. It is important to avoid injecting into the muscle, as epinephrine will cause vasodilatation (due to the action on β_2-receptors), quickly dissipating the local effects of the anesthetic and increasing its toxicity.[56]

The ring-block takes approximately 15 minutes to induce anesthesia. As soon as the donor-area skin becomes numb, tumescent anesthesia is administered by injecting larger quantities of a more dilute epinephrine solution into the mid-fat to make the area firm. The tumescence serves six purposes: 1) to widen the distance from the follicles residing in the upper fat to the nerves and larger blood vessels lying just above the fascia, 2) to increase the rigidity of the donor area, 3) to decrease follicular transection, 4) to decrease bleeding, 5) to produce more uniform anesthesia and 6) to reduce the amount of anesthetic required.

Tunescence can be achieved using a dilute solution of epinephrine (adrenaline) and lidocaine (Table 34.8) in somewhat higher concentrations than used in liposuction surgery, as this will provide additional anesthesia that is particularly important in repeat procedures or for patients with significant donor scaring.[57] In situations where there is scarring, direct cutaneous innervation to the donor area from the occipital branches can be blocked so that innervation to the donor area arrives in a rostral-caudal direction rendering inferiorly placed ring-block anesthesia ineffective. At times, when there is an excessive amount of donor scarring, even the tumescence is inadequate and the initial ring-block mixture must be injected above or directly into the scarred area to make it numb.

Table 34.8 Anesthetic Mixture

Ring-Block Component	**Concentration**	**Amount in Mixture**
Lidocaine	0.5%	= 60%
Bupivacaine	0.025%	= 40%
Na^+ Bicarb*	8.4%	1:10
Epinephrine	---	1:200 000
Volume†	**Initial Quantity**	**Boost**
Donor area	20 cc	10 cc
Recipient area	25 cc	10 cc
Tumescent Mixture for Donor Harvest Component	**Concentration**	**Amount in Mixture**
Lidocaine	0.17%	= 100%
Epinephrine	---	1:600 000

Volume†	Quantity
Donor area	30 cc

* *Used prn*
† *Volume of mixture typically used in 2000-graft session*

Follicular Unit Extraction

Follicular Unit Extraction (FUE)[2] is a conceptually simple procedure, where individual follicular units are harvested through a small circular incision created by a trephine or similar instrument. The punch cuts into the reticular dermis and the remainder of the follicular unit is literally extracted from the scalp. The advantage of this procedure is that it obviates the need for a linear incision. Difficulties lie in the intrinsic variability of each patient with respect to the ease of extraction, the increased risk of follicular transection compared to other techniques, and the organizational limitations of not being able to have multiple persons (more than two) working in parallel, as with microscopic dissection.

Follicular Unit Extraction (FUE) is appropriate for patients who have limited hair loss and who want to wear their hair so short that a linear donor scar might become visible. The procedure is also useful in patients who have healed poorly, or who have a very tight scalp. The most important application of this technique, however, is to camouflage a linear donor scar from a prior hair transplant procedure.[2]

FUE's main limitation is that it is less efficient in harvesting hair than follicular unit transplantation performed with strip harvesting. In FUT, all the hair from the optimal (central) part of the donor region can be removed and transplanted, and the resulting defect is sewn closed. In contrast, the FUE defects remain open to heal by secondary intention with significant amounts of intervening hair left behind and, therefore, a much larger region must be accessed to harvest the necessary amount of donor hair.

With Follicular Unit Extraction, the secondary-intention healing causes microscopic fibrotic changes in the donor area, distorting adjacent follicular units and making subsequent sessions more difficult. As mentioned, transection during the harvest is appreciably greater than stereo-microscopically controlled FUT. Taken together, these factors significantly limit the total amount of hair that can be accessed through FUE rendering it a less robust procedure than Follicular Unit Transplantation. In a procedure where a finite donor supply is the main constraint, inefficient use of donor tissue poses a significant problem. Table 34.9 summarizes the pros and cons of this follicular unit extraction.

The ability to perform follicular unit extraction with minimal transection varies significantly among patients. Because of this, a test measuring the ease of extraction (the FOX Test)[2] should be performed prior to recommending the procedure. Patients undergoing follicular unit transplantation should also be tested for follicular unit extraction at the time of surgery, in case the latter procedure is needed (or desired) at a future date. It is encouraging that follicular unit extraction techniques continue to improve.

Table 34.9 The Pros and Cons of Follicular Unit Extraction

Pro

- No linear scar
- Useful when the patient wants (or needs) to wear the hair on the back and sides very short
- Useful when only small numbers of grafts are needed (e.g. limited hair loss, a small touch-up procedure)
- Provides an alternative when the scalp is too tight for a primary closure or when the patient heals with widened scars
- Ideal for camouflaging donor scars that cannot be excised
- Makes it possible to harvest non-scalp hair (e.g. beard or body hair)

Con

- Requires multiple sessions to equal the size of a single FUT procedure
- The number of grafts that can be obtained is limited to 400 to 600 at a time
- Takes longer to perform and is more expensive than FUT
- Risks the eventual loss of transplanted grafts by harvesting from outside the "sweet spot" of permanent hair in the donor zone
- After large numbers of graft are harvested, fine stippled scars may become visible due to thinning of donor area
- Scarring and distortion of follicles may make further harvesting by follicular unit extraction difficult
- Maximum possible yield markedly lower than with FUT

Strip Excision

The ideal position for the donor incision is in the mid-portion of the permanent zone lying at the level of the external occipital protuberance. A 1-cm-wide donor strip is excised using two parallel blades set 1.2 cm apart. (The extra 2 mm accounts for the skin stretched from the tumescence.) A convenient harvesting device is the Rassman handle that is loaded with two #10 blades. The handle holds the blades at an angle of 30^0, making them parallel to the emergent hair.[1] The handle should hold the blades in a preangled position; otherwise, in following the angle of the hair, the surgeon may cut superficially with the upper blade while too deep into the scalp with the lower (Fig. 34.7). Once the main parallel portion of the incision is complete, a single scalpel blade is used to taper the ends into an ellipse. In general, the length of each tapered end should measure at least 1.5 times the width of the strip so that the ends lie flat (Fig. 34.8).

Alternatively, the entire excision can be performed with a long free-hand ellipse after the skin is marked.[9] This allows the angle of the blade to be adjusted as each edge is cut. On the other hand, this technique makes it harder to keep the width uniform, which is necessary for predictable graft yields. Cutting the second edge also becomes more difficult because the rigidity of the tumescence is lost. The first incision renders the second wound edge mobile and there is more distortion of the wound edge and hair follicles due to the relative elasticity of the dermis compared to the epidermis and fat.

Fig. 34.7 Donor-strip harvesting using two parallel blades on a Rassman handle pre-angled at 30^0 to allow both blades to lie flush against the scalp.

Fig. 34.8 Dissection at the tapered corner of the strip in a mid-subcutaneous plane, just below the follicles.

Donor Closure

Once the strip is removed it is immediately placed into a chilled Ringer's lactate solution. The donor wound is sutured with a running 5-0 suture made of poliglecaprone 25,[58] although a wide variety of suture materials and techniques are available.[59,60] Absorbable sutures can be placed very close to the wound edge, so close that they are quickly buried after the procedure making removal difficult. Placing sutures close to the wound edge minimizes entrapment of follicles and avoids strangulation if there is significant post-op edema. To further limit damage to follicles, the sutures should be placed approximately 4.5 mm apart and the suture should be advanced on the surface, rather than under the skin (as in traditional surgery), as this will minimize the amount of suture in contact with the follicles (Fig. 34.9).

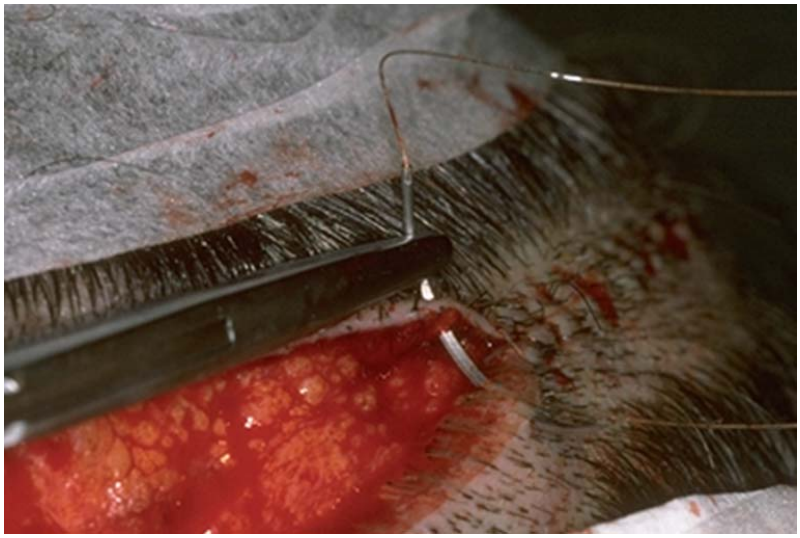

Fig. 34.9 Suturing the donor area using absorbable sutures. Note the needle track is parallel and very close to the wound edges.[58]

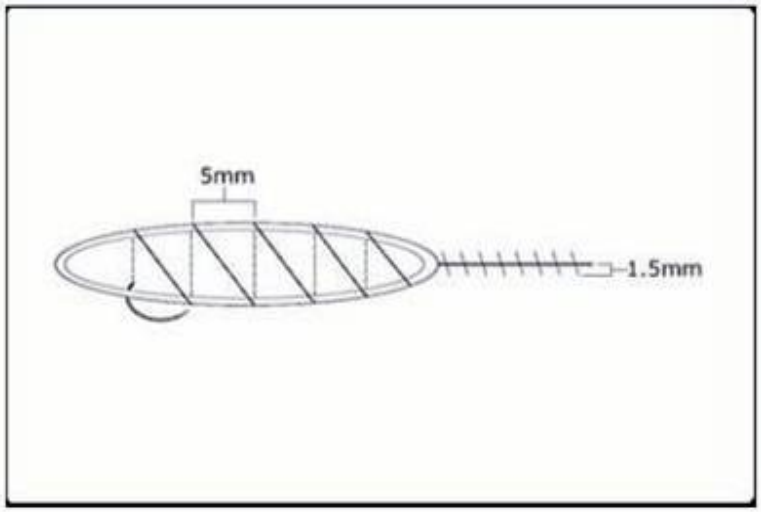

Fig. 34.10 Schematic of the suturing technique recommended for sewing the donor scalp. The spacing between loops is from 4.5 to 5 mm.[58]

The needle should be passed through the full thickness of the dermis and exit the wound edge just below it (at the level of the bulbs) without incorporating any significant amount of subcutaneous tissue. The needle track must be kept parallel to, and within 1.5 mm of the wound edge (Fig. 34.10). Particular attention should be paid to placing the needle parallel to the upper wound edge where the angle is very acute. Basic guidelines for using poliglecaprone 25 (Monocryl) sutures can be found in Table 34.10.

Table 34.10 Guidelines for Using Poliglecaprone 25 Sutures

- Plan width of donor strip so that there is little or no tension on closure.
- Use tumescent anesthesia to harvest donor strip in mid-fat.
- Use sutures no heavier than 4-0 or 5-0 gauge.
- Use a simple running stitch, advancing each loop on the skin surface.
- Keep needle parallel to, and within 1.5 mm of, wound edge.
- Incorporate epidermis and dermis only.
- Use 4.5 mm spacing between loops.

If staples are used to close the wound edges, it is important to be certain that the wound edges are flush before the staples are applied. The edges can be approximated by grasping the lower edge with a skin hook and using rat-toothed forceps to hold and slightly evert the upper edge (this requires the help of an assistant). The staples should then be placed approximately 0.6 cm apart (Fig. 34.11). Staples have virtually no tissue reactivity, but they make flush apposition of wound edges difficult and can be uncomfortable and painful to remove. In the balance we prefer absorbable sutures, though staples may be better for some patients with high density and very loose scalps.[58]

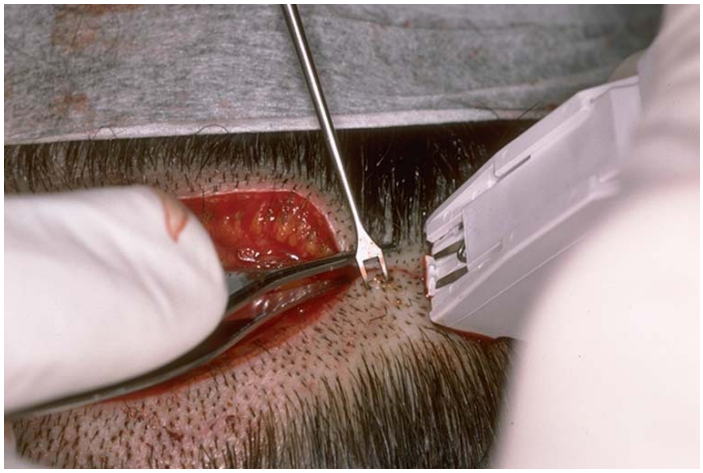

Fig. 34.11 Stapling technique illustrating very controlled apposition of wound edges, using skin hooks for the lower edge and forceps to evert the upper.[58]

Graft Dissection

Once the donor strip is removed, it is immediately placed into Lactated Ringer's solution and passed to the head member of the surgical team stationed at a stereo-microscope (Fig. 34.12).

Fig. 34.12 Close-up view of a donor strip showing the natural hair groupings at the surface, slightly curved path of the hair through the dermis and random distribution of bulbs in the fat. It is this unique anatomy that makes stereo-microscopic dissection essential in preventing follicular transection.

The strip dimensions are measured and recorded. The next step is performed under strict stereo-microscopic control in a process called "slivering."[10,35]
In one method of slivering, the donor strip is placed on its side, on a wooden tongue-depressor blade (soaked in Ringer's) with the hair pointing away from the dissector and the convex surface of the strip facing upward. For a right-handed person performing dissection, the left end of the strip is held with rat-toothed forceps in the dissector's left hand. An assistant applies tension to the strip, holding it a few centimeters away from the area being cut with rat-toothed forceps held in the right hand. Using a Personna #10 blade on a #3 blade handle held in the right hand, the dissector begins to cut the strip into 2-2.5 mm wide sections, by guiding the blade between follicular units using a one-directional fillet-like movement from the epidermal side to the subcutaneous surface. A back-and-forth sawing motion should be avoided as it will destroy follicles (Fig. 34.13, 34.14). The pieces generated are then passed along to the other members of the surgical team who complete the dissection. In the last step, the individual pieces are placed on their sides, stabilized with straight jeweler's forceps, and then dissected under the stereomicroscope with a scalpel into individual follicular units of one to four-hairs (Figs 34.15, 34.16).

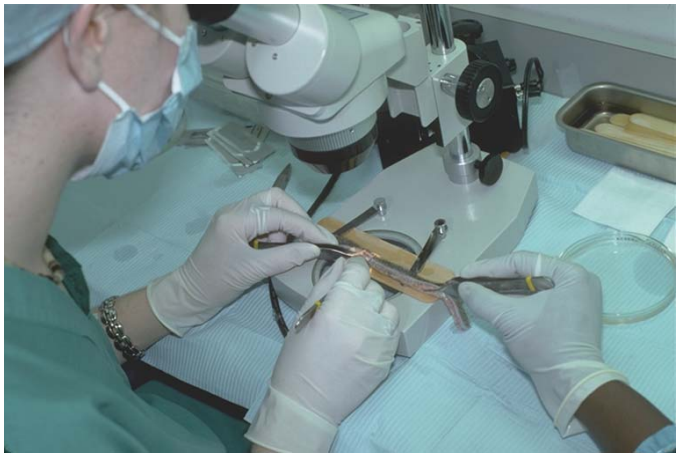

Fig. 34.13 "Slivering" the donor strip into sections.

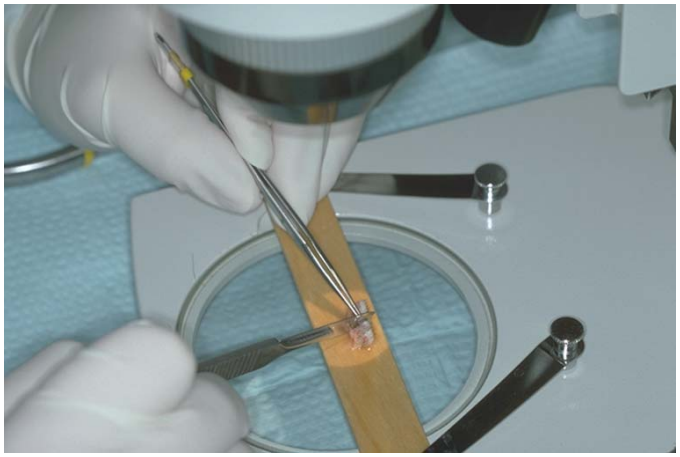

Fig. 34.14 Stereo-microscopic dissection of one section into smaller pieces.

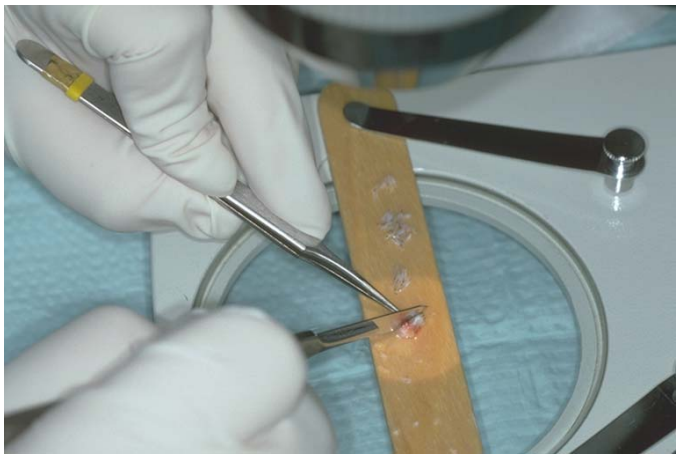

Fig. 34.15 The final step of the dissection: generating individual follicular units.

Next, the units are sorted according to the number of hairs they contain into separate Petri dishes held on ice blocks and filled with Ringer's lactate (Fig. 34.17). When a substantial number of grafts (several hundred) have been dissected, they are put into more secure plastic specimen containers and refrigerated.

Fig. 34.16 Dissected one-, two-, three- and four-hair follicular units.



Fig. 34.17 Petri dishes with one- to four-hair follicular units immersed in Ringer's lactate.

An alternate slivering method involves dissecting the donor strip into slivers as wide as one follicular unit, approximately 1 mm. The units are then isolated from the very thin strip. The key to either method is that every step is performed under stereo-microscopic control, which keeps the units intact and avoids follicular transection. It is also vital that all the pieces of the strip remain in chilled Ringer's lactate except when they are being cut. While under the microscope, they should be kept well-hydrated using 10-ml syringes containing Ringer's lactate, kept by each cutting surface.

Recipient Sites

The way recipient sites are prepared determines the critical aesthetic factors of the transplant: the angle at which the new hair grows, its distribution, its density and how natural the hair will look as it emerges from the scalp. A thorough discussion of site creation is beyond the scope of this chapter, but the four basic elements will be briefly reviewed. These are recipient site size, hair direction, site density and graft distribution, and they are covered in greater detail in Bernstein and Rassman.[8]

Recipient Sites

The sites should provide a snug fit for the graft: just large enough to accommodate a follicular unit, but not so small that insertion is difficult or traumatic.[1] Numerous instruments have been developed to create recipient sites. The main aspect to consider in choosing one is its diameter.[61] Although there are many viable options, the following are suitable for most procedures:

- a 19- or 20-gauge hypodermic needle for one-hair and thin two-hair follicular unit grafts
- an 18-gauge needle for thick two-hair and all three- and four-hair follicular unit grafts

These needles can be fitted on 3-ml syringes for ease of use, obviating expensive handles. Some physicians advocate smaller recipient sites, but this may require dividing four-hair follicular units, a technique that this author does not recommend.[35] For very fine hair, or in special situations like transplanting eyebrows, a 20-gauge (or finer) needle can be used.

Most instruments used to make sites create tiny slits as they cut through the skin, and these slits can have either a coronal (horizontal) or sagittal (vertical) orientation. The purported advantages of coronal incisions are: a more natural appearance (since the original orientation of most follicular units seems to be coronal), a fuller look and less tendency of the growing hair to elevate in the vertical plane. The purported advantages of a sagittal orientation are: greater visibility of sites, ease of graft placement, less trauma to existing hair, less damage to collagen and the underlying vasculature and less lateral (radial) splay of hair.

Hair Direction

Hair should be placed into the scalp at the angle it originally grew in, not in the direction that it is to be groomed. In general, hair anterior to the vertex transition point should point forward, with the angle becoming more acute as it reaches the anterior hairline, where it is essentially horizontal to the ground (regardless of the slope of the forehead). The direction of hair in the frontal hairline always points forward, rather than growing radially, and only deviates significantly from this as it approaches the temples (Fig. 34.18).[8]

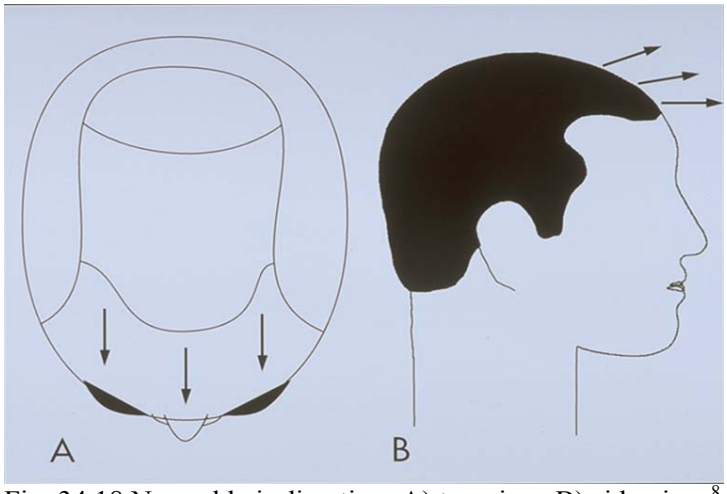

Fig. 34.18 Normal hair direction: A) top view, B) side view.[8]

Recipient Site Density

The average non-balding scalp has 100 follicular units per cm^2. Approximately 50% may be lost before there is any noticeable thinning. It would be wasteful, therefore, for more than 50% to be

replaced--especially since transplants are always performed in the face of diminished total hair volume. We generally recommend transplanting up to 25 follicular units per cm^2 into the frontal area of a balding scalp. If the larger three- and four-hair units are placed in select areas, more than 25% of the initial density can be achieved in one pass. With two procedures the ideal transplant density can be achieved in many patients.[8]

Some physicians advocate a "one-pass" procedure to achieve the final density.[35] Although this may be appropriate for some patients, the increased incidence of graft popping and desiccation, insertion injury and possible vascular compromise may lead to poor growth. For very bald patients, very dense packing does not allow coverage of an entire bald area. Moreover, transplants of more than 2500-3000 follicular units often necessitate that the grafts be out of the body so long that their survival may be diminished. It is this author's view that covering the entire bald area and then increasing density in a subsequent session is a better goal for most patients as this avoids the risks of very dense packing.

Distribution

For simplicity, the area of the scalp subject to androgenetic change can be divided into three regions: 1) the frontal region that includes the frontal hairline, 2) the top or mid-scalp and 3) the vertex or crown. The vertex transition point separates the top of the scalp from the crown (Fig. 34.19).[34] Since most social interaction takes place face to face and people generally view themselves from the front, the overall impact of the transplant is defined by the position of the frontal hairline and density of the frontal region of the scalp.

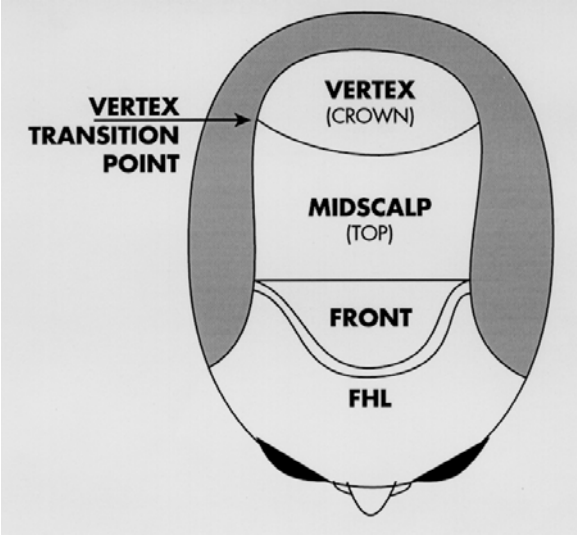

Fig. 34.19 Regions of the scalp.

For most patients who are moderately to extensively bald, or destined to be, the limitations of the donor supply make restoring the entire bald scalp to ideal density impossible. Consequently, creating the greatest density in the front part of the scalp produces the best cosmetic result. This "forward weighting" can be accomplished by putting recipient sites closer together, placing larger follicular units (i.e. those with three and four hairs) in those sites, or by doing both.

In general, recipient site density should be the highest in the front part of the scalp and gradually tapered toward the crown. In contrast, the largest follicular units should be placed in the forelock region of the scalp. This overlapping distribution of sites and follicular unit grafts may

be visualized in Figure 34.20. It is explained in greater detail in the paper, The Aesthetics of Follicular Transplantation.[8] The pattern serves two functions: it creates a natural central-forelock density without the need for spacing sites closer towards the mid-scalp (where the blood supply can most easily be compromised) and ensures the most natural look by placing the larger follicular units in a forward-central position, but away from the frontal hairline. Density in the forelock area brings about a "patterned look" and avoids the diffuse thinning that often results when small grafts are evenly distributed over the scalp.



Fig. 34.20 Schematic of "forward weighting," achieved by close placement of recipient sites dark grey area), and central density, accomplished by placing larger follicular units in the forelock area (dark brown oval).

Practically every patient has enough donor hair to provide at least light coverage extending to the vertex transition point. This is a natural stopping point since, even if the crown continues to enlarge, transplants performed to this point will still look natural without additional surgery. Transplants should be extended past the vertex transition point into the crown only when there is adequate hair to create a swirl and follow the hair loss if the balding progresses. The indications for transplanting the crown are discussed in detail in Follicular Transplantation: Patient Evaluation and Surgical Planning.[7]

The distribution of grafts in the first transplant session should, in general, be symmetric. However, once the first transplant has had a chance to grow and the patient is willing to commit to styling his hair in a specific pattern, "side weighting" should be considered. This is accomplished either by placing a greater proportion of the grafts on the parted side of the scalp, using larger follicular units on that side, or doing both. It results in increased fullness when one's hair is combed to the side. In situations where there is a great imbalance in the supply/demand ratio, such as after scalp reductions or old plug procedures, a more exaggerated form of "side weighting" should be considered. In this case the follicular unit grafts are concentrated on the front and part side of the scalp but widely scattered in the top and back.[8] (Fig. 34.21)

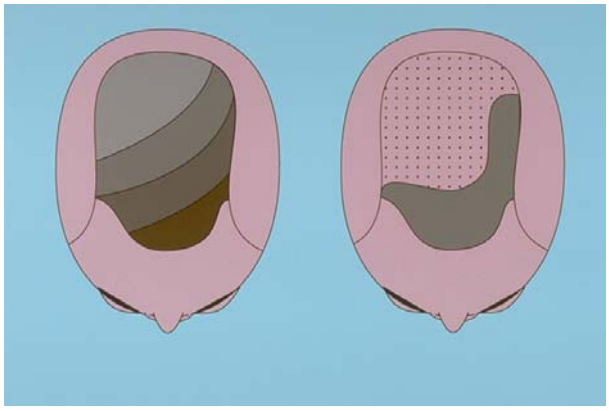

Fig. 34.21 Left: Schematic view of left to right "side weighting." Right: Extreme side weighting employed when the donor supply is severely diminished.

The number of follicular unit grafts required in the first and subsequent transplant sessions, with and without crown coverage, can be found in Tables 34.4 and 34.5.

When the follicular units are completely dissected and grouped in Petri dishes, they are placed at the head of the operating table on ice blocks. Graft placement, carried out in a front-to-back pattern, begins at the frontal hairline with one-hair follicular units. In a typical transplant, approximately 250 one-hair units are used for the leading edge of the frontal hairline, immediately followed by two-hair grafts. Three- to four-hair units are concentrated in the forelock area (Fig. 34.22), while toward the back and sides the pattern is reversed so that the three- and four-hair units are always central to the one- and two-hair units.

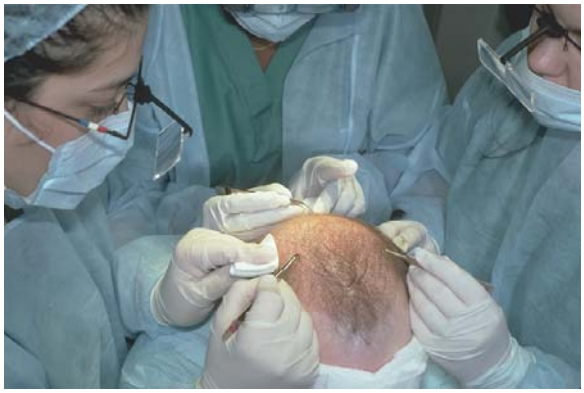

Fig. 34.22 Staff using loop magnification and curved jeweler's forceps to place follicular unit grafts into pre-made recipient sites.

Approximately 20-30 grafts are transferred at one time from the dish to the index finger, held on the finger in a droplet of Ringer's solution. The grafts are inserted using curved jeweler's forceps. Each graft should be carefully grasped by the fat at its bottom or at its edge, not at the germinative center. In the two-hand technique, gauze, held between the free fingers of the hand holding the grafts, is used to keep the partially inserted grafts in place as the forceps are repositioned higher along the length of the graft, to facilitate the last phase of insertion.

In an alternative method, termed "stick and place," the grafts are inserted at the same time that the recipient sites are made.[35] In this technique, the needle that is used to make the recipient hole can also serves as a "shoehorn" to help guide the graft into the site. The advantage of this method is that it eliminates the possibility that sites may be left unfilled or that two grafts may be placed into one site (piggybacking). It also moves the surgery along faster since the staff doesn't need to wait for the surgeon to make the sites and they don't need to search for the ones that are empty.

On the other hand, there is more bleeding when sites are made concomitantly with graft placement (decreasing visibility) and there is an increased risk of the grafts popping and then drying out on the surface of the scalp. In addition, the staff must make judgments regarding the angling and distribution of the sites they are creating at a time when they must also be focusing on the technical aspects of graft insertion. This leaves many of the aesthetic decisions in the hands of the technicians, who are actively engaged in stick and place, rather than with the physician who could take a more strategic view of the procedure.

Patient Disposition

After graft insertion is complete, the scalp is cleaned with distilled water, bacitracin zinc ointment is applied to the sutures and a head-band type pressure dressing is placed over the donor area. The transplanted area is covered with a surgeon's cap. Prior to leaving, patients are given verbal and printed post-op instructions, a neck pillow and medications for sleep, pain and hiccups (Table 34.11). Patients leave the office wearing a bandana covering the cap and the headband. It is worth stressing that patients given sedatives or pain medication do not drive after surgery.

Table 34.11 Medications Commonly Used in Hair Transplantation

Class	Medication	Use
Topical anti-bacterial	Hibiclens	Preoperative
Systemic antibiotics	Dicloxacillin, Cephalosporin	Intraoperative prophylaxis*
Sedative/hypnotic	Diazepam, Aprazolam	Intraoperative sedation
Corticosteroids	Betamethasone	Postoperative swelling
Topical antibiotics	Bacitracin ointment	Postoperative care, donor area
Opiates	Hydrocodone	PRN, postoperative pain
Anti-hiccup	Chlorpromazine	PRN, hiccups
Analgesia	Nitrous oxide[55]	PRN during injections†
Wound healing promoters	Copper-peptide	Postoperative healing†
Hair growth promoters	Finasteride, minoxidil	Pre and Postoperative*

**See Text*
†Not used in our practice

OPTIMIZING OUTCOMES

Transition zones

A soft, natural hairline is the hallmark of an optimal transplant. However, careful observation of a normal frontal hairline reveals that there is no actual "line," but rather an irregular, slightly asymmetric "transition zone" or gradation of follicular units of increasing size and density. This is what should be replicated in the transplant (Fig. 34.23a-b). Transition zones are not limited to the frontal hairline; they must be re-created wherever the edge of the transplanted area is visible. In Figure 34.23d, one notes that transition zones have been created at the frontal hairline, sides and vertex transition point leading to the crown.

Although there are an infinite number of ways to create a transition zone at the frontal hairline, the placement of approximately 50-100 single follicular units in front of a band of staggered single units, one to three rows deep, will usually achieve the appropriate softness. This should be followed by two-, three- and eventually four-hair units, but the larger units should be more centrally located (Fig. 34.23C). With finer hair, larger units may be placed closer to the hairline. It is important to limit the depth of the single hair units, or the zone will appear too thin.

Visibility

Pre-making all the recipient sites prior to graft insertion helps to control bleeding and limits the need for epinephrine (adrenaline) (Fig. 34.23D). It initiates the "extrinsic pathway" so that coagulation can begin before the grafts are introduced and allows for easy cleaning of the recipient area of any blood or coagulum, without the risk of dislodging grafts. It also makes it possible to place sites close together without a concern for grafts in adjacent sites from popping. Most importantly, it provides maximum visibility in placing phase of the procedure.[46]

If the initial sites are scattered, they tend to cause the cutaneous vasculature of the scalp to "clamp down," increasing visibility for subsequent passes and allowing the skipped areas to be filled in. When pre-making sites, the logistics of matching the number of sites to the number of grafts can be solved by making "projections" of the anticipated number of grafts while the dissection is still in progress.

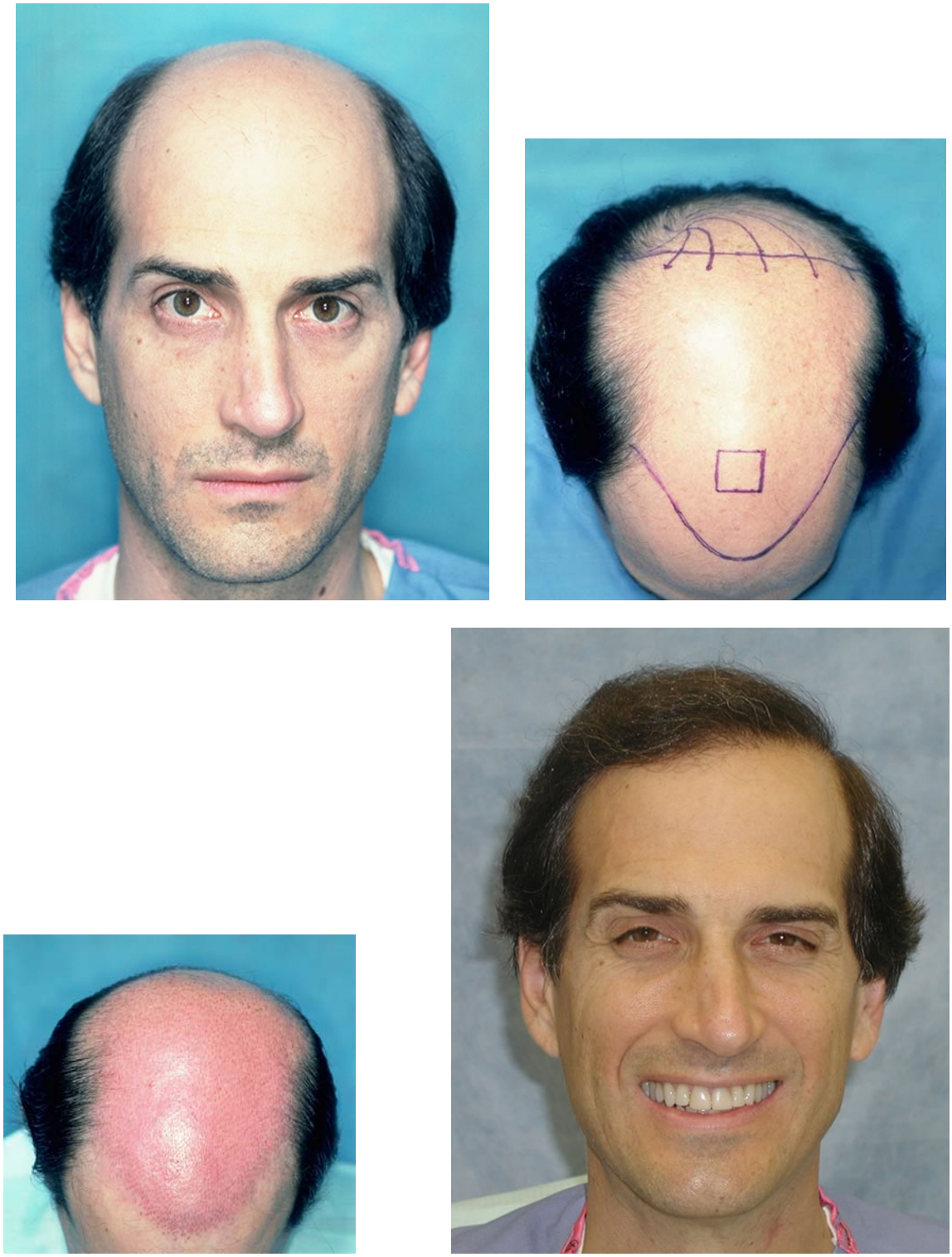

Fig. 34.23. A) Pre-op. B) One year after two sessions totaling 4295 follicular unit grafts. C) Pre-op markings of the planned procedure. D) First session just prior to placement, showing the distribution of 2355 recipient sites.

Recipient Site Influences

Some hair characteristics, such as waviness, are governed by the recipient site. When individual follicular units are placed into very small wounds, there is little fibrotic reaction to the grafts and the recipient area can exert its influences on hair growth. In Figure 34.24, note the delicate wave produced by the recipient scalp. Because the cylindrical shape of the follicular unit gives no clue as to its orientation, it would be impossible for the surgeon to intentionally rotate the hair to product this effect.

Fig. 34.24 A) Pre-op, Norwood Class VI, with very fine, blonde hair and a donor density of 2.5 hair/mm^2. B) One year after two sessions of 2678 and 1836 follicular unit grafts.

Fig. 34.25 A) Pre-op of Early Norwood Class VI. B) One year after one session of 2520 follicular unit grafts.

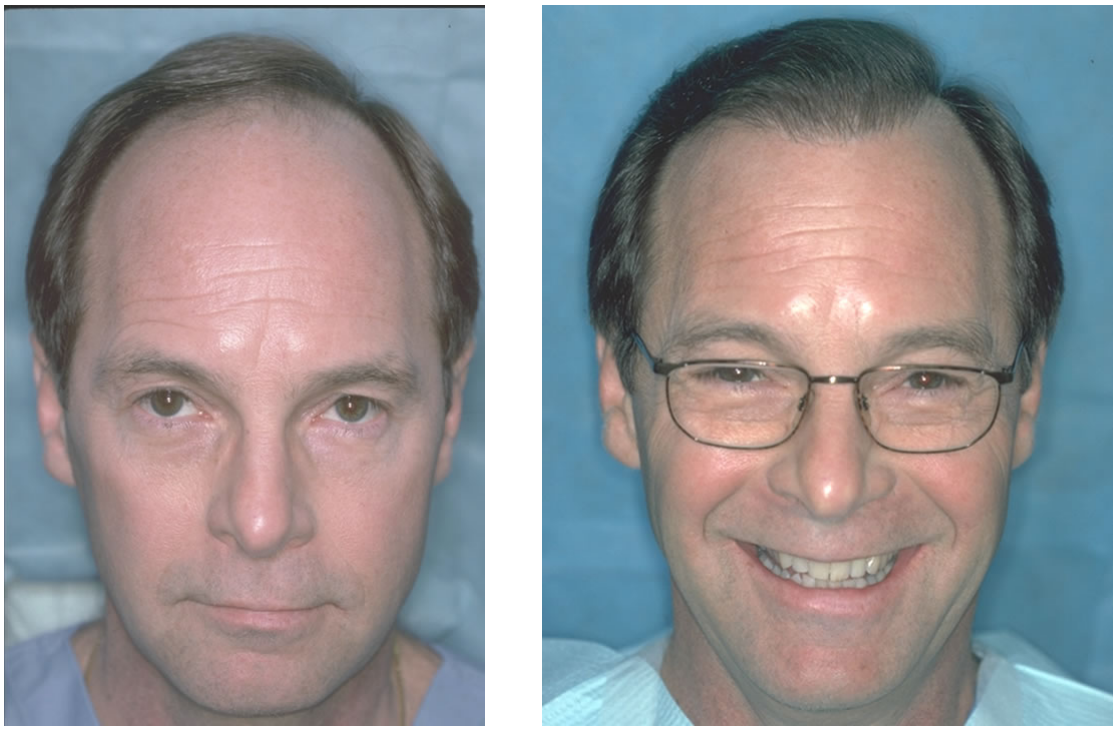

Fig. 34.26 A) Pre-op, Early Norwood Class V. B) One year following two sessions of 2105 and 1665 follicular unit grafts.

Fig. 34.27 A) Pre-op, Norwood Class V. B) Integrating hair with a persistent frontal forelock (one year following two sessions of 2133 and 1,171 follicular unit grafts.)

Fig. 34.28 A) Pre-op of 46-year-old early Norwood Class IVA with wavy, medium-coarse hair. B) Post-op after two sessions of 2085 and 1438 follicular unit grafts.

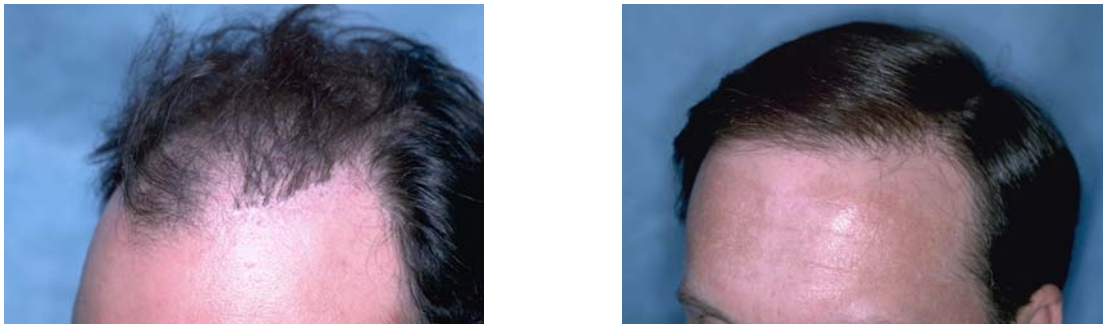

Fig. 34.29 A) Pre-op showing large grafts forming a literal wall of plugs. B) Camouflage from one session of 1818 follicular units.

Hair Direction

When the hair is planted at the frontal hairline in its natural forward-pointing direction, combing it back causes it to bow, giving it the appearance of fullness. A common mistake is to point the hair in the direction that the patient plans to comb their hair; this makes the hair lie flat and bodiless when groomed. On the other hand, as the frontal hairline approaches the temples, the hair direction should be abruptly changed, so that it is angled downward and lying very flat on the scalp. Perfect integration of the frontal hairline with hair on the sides and temples is essential if the transplant is to look completely natural (Fig. 34-25).

Hairline Placement

If it is look natural throughout the patient's life, the transplanted hairline must simulate that of a mature adult. In the adolescent male, the frontal hairline touches the top crease of the brow when the eyebrows are raised (i.e. the hair begins at the upper border of the frontalis muscle). In a mature adult, the mid-portion of the frontal hairline rests approximately one finger-breadth (1.5-2 cm) above the brow crease. Although the degree of temple recession can vary dramatically in the normal adult hairline, the mid-part of the frontal hairline is crucial in framing the face.[1,8] Significant bitemporal recession was built into the restoration of the patient in Figure 34.26, yet the forward-placed mid-portion sets his facial features in the correct proportions.

Forelock Integration

A persistent frontal forelock poses an interesting dilemma. When hair is transplanted around the forelock, the patient may be left with a gap in his frontal hairline if the forelock eventually disappears. On the other hand, it is wasteful to add hair to a forelock with adequate density that may persist for years. The solution is to check for miniaturization with a densitometer. The patient in Figure 34.27 had miniaturization in his forelock greater than 50%, suggesting that it would not be stable over time. Two sessions were used to integrate transplanted hair into the resident terminal hair of the forelock, producing a central density that should persist for many years.

Optimizing Density

One of the beauties of FUT is the ability to sort the three- and four-hair units and place them in the forelock area, creating a density significantly greater than if the grafts were evenly distributed. This is possible because the compactness of the follicular unit allows four-hair grafts to be placed into very small sites.[6,8] In certain instances, follicular units may contain more than four hairs, and adjacent follicular units are occasionally so close together that they can fit into a small recipient site.[62,63] However, as long as these "grouped grafts" are placed in a central location and the recipient wounds are kept small, this technique can add density without risking an unnatural look. It is important to keep in mind that ultimate density depends on the absolute number of hairs moved rather than the size of the grafts.[64] Using grafts larger than follicular units always risks that the transplant may look unnatural. The patient in Figure 34.28. achieved a very dramatic frontal density in two sessions using the technique of follicular unit sorting.

Creating Camouflage

A sizable part of many practices involves repairing transplants performed with older techniques. FUT is ideal for this because of follicular units' small size and high hair count.[65,66] Often fixing a

pluggy look requires graft excision (with reimplantation) prior to the actual transplant. However, the patient in Figure 34.29. had a row of plugs set far enough back from his frontal hairline that camouflage with follicular units alone was sufficient for the repair.

Automation

Short of cloning follicular units in a Petri dish, the future in FUT optimization lies in the development of automated devices that can harvest the donor strip, isolate individual follicular units, create recipient sites and insert grafts--all without the risk of human variability or error. A number of creative instruments have been designed toward this end, but thus far their success has been limited.[67-70] Much of the difficulty lies in the inherent variability of the human scalp and the follicular unit itself. The full automation of a procedure that is labor intensive, organizationally complex and dependent on the aesthetic judgment of the surgeon remains a formidable challenge.

POSTOPERATIVE CARE

Patients are called at home the day after the procedure and seen in our office one week post-op. They come in again 10 months later to assess growth, have their pictures taken and discuss the possibility of additional surgery. Those with questions or concerns are seen as frequently as needed. Table 34.12 summarizes typical post-op instructions.

Table 34.12
Summary of Post-Op Instructions Following Follicular Unit Transplantation

Care of Transplanted Area
Shampoo every three to four hours the day following surgery, and then twice daily until your one-week post-op visit. Be especially careful when cleaning the transplanted site in the first few days so that the grafts will not be dislodged. However, a thorough but gentle rinsing of the recipient area will minimize crusting and make the transplant less noticeable. When shampooing and rinsing the transplanted area, be gentle for the first two weeks following surgery. Do not rub, pick or scratch, as this may dislodge grafts.

Care of Sutured Area and Non-Transplanted Parts of Scalp
Gently wash the sutured area with your fingertips using copper peptide containing shampoo. Shower water may hit the sutured area in the back of your scalp directly. You may use a hair dryer set on warm, but not hot. Do not use any scalp or hair coloring agents for at least two weeks after your procedure.

Post-Op Medications
After your procedure, you will be given sleeping medication, pain pills and medication for hiccups.

Itching
You may experience some itching either in the transplanted area or sutured area following your procedure. Hydrocortisone ointment may be applied locally to the areas that itch as needed, up to four times a day.

Swelling
You will be given an injection of cortisone during your procedure to decrease swelling after surgery. If there is significant swelling, it usually occurs around the second to fifth day post-op and should not be cause for concern. It resolves by itself after a few days and does not require any special treatment. Cool, wet dressings may be placed over the swollen area, but make sure they do not touch the grafts.

Bleeding
Before you leave the office, all bleeding will be controlled. Rarely some bleeding may occur after the procedure. If this happens, apply firm, continuous pressure on the area. If you are unable to contact us through our pager, go to the nearest emergency room and show our instructions to the physician on duty.

Exercise, alcohol, smoking and other restrictions
Avoid direct trauma to the head for two weeks after the procedure, and abstain from sexual intercourse, alcohol use and smoking for three days after the procedure. After two weeks, you may resume your normal daily activities.

Sun
Avoid unprotected exposure to sunlight for three months. Wear a hat when you are going to be outside or use a strong sunscreen with a SPF of 30+.

Infection
Redness, swelling and slight tenderness are to be expected for the first few days after a procedure. Persistent swelling, pain or tenderness in the sutured area may be a sign of infection. Fever and/or chills are indications of infection as well. There also may be a discharge or puss in the suture line. If any of these conditions should occur, please contact the office.

Numbness
Scalp numbness, tingling or similar sensations may occur temporarily. This generally disappears within a few weeks to months, as nerve endings regrow.

Hair-Loss Medications
Minoxidil 5%: If you plan to continue this medication, resume it one to two weeks after the procedure.
Finasteride 1mg: This medication should not be discontinued for the surgery.

PITFALLS AND THEIR MANAGEMENT

A number of problems arising in hair transplant surgery have been well described in the literature. Table 34.13 summarizes them, along with their most likely cause (though some etiologies may be multi-factorial) and methods for preventing and managing them should they occur.[12,71,72]

Table 34.13 Problems Encountered in Follicular Unit Hair Transplantation and their Management

Problem	Cause	Prevention	Treatment
Syncope	Anxiety, Vaso-vagal reaction	Pre-medicate with valium or atropine, administer anesthesia with patient lying flat	Lie patient supine and elevate legs
Anxiety, palpitations	β_1- and α-adrenergic effects of epinephrine	Administer epinephrine slowly, pre-medicate with valium	Patience (the half-life of epinephrine is short); Lidocaine for arrhythmias
Hypertension and bradycardia	Epinephrine (adrenaline) interaction with β-blocker	Use selective β_1-blockers	α-adrenergic blockers; treat as cardiac emergency
Agitation, confusion, perioral numbness	Lidocaine toxicity	Use more dilute anesthetic mixture, use ring-blocks rather than local infiltration	Intravenous fluids, oxygen, ventilate, Diazepam; treat as cardiac emergency
Pruritus, urticaria, angioedema	Allergic reaction/anaphylaxis to drugs or food	Careful history	Oxygen, epinephrine (adrenaline) subcutaneously
Excessive bleeding	Elevated blood pressure, non-steroidal anti-inflammatory agents	Discontinue anti-platelet agents prior to surgery, continue anti-hypertensive medications day of surgery, pulse oximetry	Operate with patient seated; with elevated blood pressure, consider anti-hypertensives
Post-op edema	Surgical trauma, buffered anesthetic	Keep recipient sites small, pre- and post-op systemic cortico-steroids	Head elevation, additional post-op corticosteroids
Sterile folliculitis	Growing hair trapped by epidermal overgrowth	Keep grafts slightly elevated	Resolves spontaneously; incision and drainage if persistent
Cyst formation at graft site	Foreign body reaction to imbedded graft	Avoid piggybacking one graft over another in the same site	Incision and drainage, topical and/or systemic antibiotics
Bacterial folliculitis	Picking, scratching, poor hygiene, 2^0 to infected sterile folliculitis or cyst	Frequent post-op showering, topical cortico-steroids for pruritus	Topical and systemic antibiotics
Infected donor wound	Suture bites too large/tight; with post-op edema, causes	Harvest a narrower donor strip under less tension, change	Systemic antibiotics; if severe, leave portion of donor area

	vascular compromise	suturing technique	to heal by 2^0 intention
Widened scar in donor area	Donor strip too wide or placed too low, patient tendency to heal with stretched scar	Careful history, conservative donor strip located at level of occipital protuberance	Excision +/- (can worsen scar), Follicular Unit Extraction
Raised donor scar	History of keloids, racial susceptibility, incision placed too low	Careful history, patient selection, test biopsy	Intra-lesional corticosteroids
Persistent numbness or paresthesias in the back of the scalp	Transection of branches of the occipital nerves	Limit donor depth to deep subcutaneous layer, use tumescent anesthesia	Subsides spontaneously if the cut nerve branches were small
Hiccups	Possible injury to C2-C4, indirectly stimulating the vagus or diaphragmatic nerves	Limit donor depth to deep subcutaneous layer, use tumescent anesthesia	Chlorpromazine
Hair texture changes	Trauma to grafts, sebaceous glands removed in dissection?	Careful atraumatic dissection and placing, avoid trimming follicular units too close	Usually resolves spontaneously
Skin texture changes	Recipient wounds too large	Make wounds no larger that the equivalent size of a 19-g needle at the frontal hairline	Add coverage with one- and two-hair follicular units at the frontal hairline using very small sites
Hair loss in recipient area related to the procedure	Telogen effluvium[73]	Possibly effective: small surgical wounds, limit epinephrine, pre-treat with finasteride	Terminal non-miniaturized hair should return spontaneously, finasteride
Hair loss in donor area	Strangulation of follicles by sutures, transection of follicles during harvest	Narrower donor strip, meticulous suturing techniques	Follicular Unit Transplantation, Follicular Unit Extraction, local excision
Failure of transplanted hair to grow	Desiccation,[74] crush injury,[75] transection,[76-78] grafts out of the body too long[48]	Keep grafts well hydrated in an isotonic solution, careful microscopic dissection and handling	None

Although FUT eliminates many of the shortcomings of the older techniques, such as a "pluggy" look, a "moth-eaten" donor area or midline scalp reduction scars, poor aesthetic judgment and techniques that compromise graft growth can still lead to problems. Perhaps because FUT requires large numbers of grafts (using a significant portion of the donor area at one time), because so many staff members are involved in the process, and because some of the problems of small graft procedures are very difficult to correct, improperly performed follicular unit transplantation can pose a greater risk to patients than traditional grafting. The risk is compounded by the fact that many physicians perceive FUT as a safe, risk-free procedure and describe it to patients as such.

The remainder of this section will focus on some of the most common mistakes made by FUT practitioners, particularly in the areas of planning, transplant design and handling large numbers of small grafts. These problems and how they may be avoided are summarized in Table 34.14.

Table 34.14 Twelve Common Pitfalls in Follicular Unit Transplantation

1. Operating on patients that are too young or prior to medical therapy
2. Failing to identify low donor density prior to surgery
3. Failing to identify a tight scalp
4. Harvesting a donor strip that is too wide
5. Placing the donor incision too low or too high
6. Using a multi-bladed knife
7. Crushing grafts during insertion
8. Allowing grafts to dry
9. Placing the frontal hairline too far forward
10. Creating a hairline that is too broad
11. Angling hair in the wrong direction
12. Attempting to cover an area that is too large

Operating on Patients That Are Too Young or Before Medical Therapy

Patents in their early twenties have their flat adolescent hairline and original density fresh in their memory. A transplant designed with enough frontal and temporal recession to look good ones entire life will rarely satisfy a younger patient. Creating a density that is ideal for a younger person will not leave enough hair in reserve if there is further loss. In addition, at this age the extent of future balding is difficult to even reasonably anticipate. For these reasons, surgery should rarely be considered in patients with androgenetic alopecia younger than 25.

Often doctors begin medical therapy and schedule surgery at the same time. However, if there is a possibility that using a medication, such as finasteride, can make transplantation unnecessary, then the medication should be used for at least a year before any decision on surgery is reached. Medication should be the first line of therapy for all younger patients with androgenetic alopecia, regardless of the degree of their hair loss.

Failing to Identify Low Donor Density Prior to Surgery

Section 4, "Patient Evaluation and Surgical Planning," stressed the importance of assessing patients' donor supply with densitometry. A low donor density, generally less than 1.5 hairs per mm^2, usually indicates that donor supply is insufficient to create adequate density or coverage, rendering the procedure inadvisable. An exception might be an older person with very conservative goals. High miniaturization in the donor area, particularly in a person under the age of 30, suggests Diffuse Unpatterned Hair Loss (DUPA) and is a contraindication to surgery.[7]

Transplanting patients with low donor density will also risk a visible scar if the hair is worn short. FUE is not appropriate in such cases, since it further limits the total available hair. In fact, since the contrast between bald and non-balding scalp in patients with low donor density is naturally low, their best option tends to be wearing their hair short, to decrease the contrast even more (rather than having surgery).

Failing to Identify a Tight Scalp

Assessing scalp laxity is an underappreciated aspect of the patient evaluation, probably because it is difficult to quantify. However, a tight scalp severely limits the total amount of harvestable donor hair and can constitute a contraindication to surgery, except when patients have extremely conservative goals or are expected to experience only limited balding. The constraints that low scalp laxity impose generally manifest themselves after the first transplant session. Though laxity should be judged in the pre-op evaluation, the intra-operative assessment, made while suturing, is most accurate in predicting future difficulties. Therefore, every operative report should include a record of the ease of closure and intra-operative suture tension.[7]

Harvesting a Donor Strip That Is Too Wide

In large sessions, it can be tempting to take a slightly wider donor strip in order to conserve on length. A strip that is 25 cm by 1 cm, for instance, can be shortened by 6 cm if widened by just 3 mm--and yield the same amount of hair. However, a wide strip puts unnecessary tension on the donor closure and is probably the most common cause of widened scars. If larger sessions are appropriate, and the scalp lacks adequate mobility, the surgeon should consider a longer incision rather than a wider one.

If a wide donor strip has been identified as the likely cause of a stretched scar, it is advisable to wait at least eight months, to give the scar a chance to mature and regain some of its original laxity. When the next excision is made, the strip should measure at least 3-6 mm narrower than the previous one. Attempts to remove the entire width of the old scar invariably lead to a reoccurrence, or worsening, of the old scar. To facilitate healing, the new excision should extend to the patient's hair-bearing edge.

Unfortunately, attempts to re-excise scars commonly result in either no improvement or an even wider defect. For this reason, we have been using Follicular Unit Extraction to place hair directly into the scar as our primary treatment.

Placing the Donor Incision Too Low

The location of the donor incision greatly affects scalp mobility. The ideal position for it is in the mid-portion of the permanent zone that lies, in most people, at the level of the external occipital protuberance and the superior nuchal line. The muscles of the neck insert into the inferior portion of this ridge, so an incision below this anatomic landmark will be impacted by the muscle movement directly beneath it. A stretched scar in this location is extremely difficult to repair since re-excision, even with undermining and layered closure tends to heal with a wider scar. To

compound the problem, one is more likely to cut through fascia with a low donor incision; and once the fascia has been violated, the risk of widening the scar rises considerably.[36]

In addition to the slightly greater risk of a widened scar, the main problems of harvesting hair too high are lack of permanence of the transplanted hair (since it may be subject to androgenic alopecia) and future visibility of the scar were the donor fringe to narrow further. Incisions made too high are best left untreated, unless the scar is wide and poor surgical technique has been identified as the cause. The temptation to transplant permanent donor hair into a high scar should be resisted, as progressive balding would isolate the hair-bearing scar, presenting new cosmetic problems.

Interestingly, in the case of young patients with traumatic scars and hair-loss patterns that are still unclear, Follicular Unit Extraction can function as a hedge against this risk. If the hair is harvested from the immediate vicinity of the scar, any future balding will affect the transplanted hair in the scar at the same rate as the hair surrounding it.

Using a Multi-Bladed Knife

In order to save time, doctors performing large transplants may use a multi-bladed knife (one with three or more blades) for harvesting donor tissue. The resulting pre-sliced multiple thin strips are much easier to work with than a single intact strip. Unfortunately, harvesting this way causes unacceptable levels of follicular transection while destroying the naturally occurring follicular unit and is therefore incompatible with FUT.[10]

Crushing Grafts During Insertion

Proper placing technique necessitates the use of forceps to grasp the graft by the fat below the bulb or by the dermis alongside the hair shaft in order to avoid damaging the germinative components of the follicle. Though placers often exercise enormous care while initially grasping the graft, there is a tendency to become rougher when repositioning the forceps for further inserting, replacing a popped graft or transferring grafts from the holding solution to the fingers. Since follicular units and other small grafts are particularly susceptible to crush injury, improper handling can more than negate the benefits of careful stereo-microscopic dissection.[73, 74]

Allowing Grafts to Dry

An elegant study using electron microscopy has shown that desiccation is by far the most significant form of injury to grafts and makes them much more susceptible to other forms of injury, such a mechanical trauma and warming. Grafts should therefore be kept well-hydrated with chilled isotonic solution (such as Ringer's lactate) from the moment the tissue is harvested until the time they are reinserted into the scalp.[75]

Placing the Frontal Hairline Too Far Forward (Too Low)

Despite the fact that individual follicular units at the hairline in themselves look natural, their proper placement is no less important than in traditional grafting. The frontal hairline should be placed no lower than 1.5 cm above the upper brow crease.[1, 8] Particularly if the underlying skin is normal, follicular units placed too low can be removed with an alexandrite (755 nm) or diode (800, 810 nm) laser. Electrolysis is more difficult and time-consuming with transplanted follicles, but should also be considered. Punch excision is too imprecise for very small grafts and risks scarring.

Creating a Hairline That is Too Broad

Since significant temporal recession is characteristic of the normal adult male hairline, a broad, flat transplanted hairline will not age well and can cause cosmetic problems if baldness becomes extensive. The treatment is the same as with low hairlines, but it should be noted that if grafts larger than follicular units were used, and/or if there is scarring of the recipient skin, punch excision with reutilization of the hair may be indicated.

Angling Hair in the Wrong Direction

As noted earlier, in the front and top part of the scalp, hair grows in a distinctly forward direction, changing to a radial pattern as it approaches the crown. It emerges from the scalp at an acute angle, with the hair lying practically flush to the skin at the temples.

There has been a tendency among some hair restoration surgeons to transplant grafts perpendicular to the skin--probably due to the fact that the mechanics of the old plug procedures made sharp angling technically difficult. The cosmetic consequence of this is most apparent at the frontal hairline. When the hair is perpendicular, the viewer's eye is guided to the base of the hair shaft where it inserts into the skin; conversely, when hair is transplanted in its natural, forward-pointing position, it is bowed by grooming and the eye settles on the body of the hair shaft.

When grafts at the frontal hairline are transplanted in a radial direction, combing the hair in any style becomes problematic and invariably results in an unhappy patient. As with low or broad hairlines, hair that is angled in the wrong direction, particularly in the frontal hairline, should be removed.

Attempting to Cover an Area That Is Too Large

Attempting to cover an area greater than the donor supply can adequately fill may leave cosmetically important areas thin or untransplanted. In general, *the first region to bald is the area where you should be most hesitant to transplant.* Recession at the temples and thinning in the crown are usually the earliest manifestations of baldness, but they are acceptable, especially as patients age, so these areas may be left untransplanted. The central forelock region, however, is generally late to bald, but when balding occurs, the patient loses the frame to his face and its restoration becomes essential.[7]

Whether or not these areas need coverage at the time of the initial transplant, an adequate amount of hair must always be reserved for critical areas, such as the forelock and top of the scalp. If donor reserves are limited, the transplantation of less critical areas should be postponed or avoided all together.[7]

SUMMARY

Developed within the past decade, Follicular Unit Transplantation has emerged as both the standard and the cutting edge in surgical hair restoration. In conserving donor hair, achieving optimal coverage and creating a natural look, FUT represents a considerable advance over earlier methods of hair restoration. Appropriately, it also demands considerably more from its practitioners. Surgical teams must develop the skill and stamina for the delicate handling of large numbers of follicular unit grafts, while surgeons must cultivate a keen aesthetic sensibility with regard to transplant design and graft placement.

In view of the psychological aspects of hair loss, Follicular Unit Transplantation requires a thorough preoperative assessment to understand the patient's expectations, a careful examination to determine if surgery is appropriate and, most importantly, the establishment of

realistic goals. If the surgical route is chosen, meticulous attention to detail is required in every aspect of the procedure so that these goals may be realized. It is a daunting task for the hair restoration surgeon and surgical team to develop the necessary expertise for perfecting Follicular Unit Transplantation; but when they do, their work can benefit patients for their lifetime.

REFERENCES

1. Bernstein RM, Rassman WR, Szaniawski W, Halperin A. Follicular transplantation. Intl J Aesthetic Rest Surg 1995; 3:119-132.
2. Rassman WR, Bernstein RM, McClellan R, Jones R, et al. Follicular unit extraction: minimally invasive surgery for hair transplantation. Dermatol Surg 2002; 28(8):720-727.
3. Headington JT. Transverse microscopic anatomy of the human scalp. Arch Dermatol 1984; 120:449-456.
4. Rassman WR, Pomerantz, MA. The art and science of minigrafting. Intl J Aesthetic Rest Surg 1993; 1:27-36.
5. Limmer B: Thoughts on the extensive micrografting technique in hair transplantation. Hair Transplant Forum Intl; 6(5):16-18, 1996.
6. Bernstein RM, Rassman WR: The logic of follicular unit transplantation. Dermatologic Clinics 1999; 17(2):277-295.
7. Bernstein RM, Rassman WR: Follicular transplantation: patient evaluation and surgical planning. Dermatol Surg 1997; 23:771-784.
8. Bernstein RM, Rassman WR: The aesthetics of follicular transplantation. Dermatol Surg 1997; 23:785-799.
9. Limmer BL. Elliptical donor stereoscopically assisted micrografting as an approach to further refinement in hair transplantation. Dermatol Surg 1994; 20:789-793.
10. Bernstein RM, Rassman WR, Seager D, Shapiro R, et al. Standardizing the classification and description of follicular unit transplantation and mini-micrografting techniques. Dermatol Surg 1998; 24:957-963.
11. Seager D. Binocular stereoscopic dissecting microscopes: should we use them? Hair Transplant Forum Intl 1996; 6(4):2-5.
12. Stough DB, Haber RS, eds. Hair replacement: surgical and medical. St. Louis: Mosby; 1996.
13. Unger WP. Different grafts for different purposes. Am J Cosmetic Surg 1997; 14(2):177-183.
14. Unger WP. Laser hair transplanting 1997. Am J Cosmetic Surg 1997; 14(2):143-148.
15. Bernstein RM, Rassman WR: Laser hair transplantation: is it really state of the art? Lasers in Surg Med 1996; 19:233-235.
16. Norwood OT. Scalp reductions: are they necessary? Hair Transplant Forum Intl 1993; 3(6):1-7.
17. Bernstein RM. Are scalp reductions still indicated? Hair Transplant Forum Intl 1996; 6(3):12-13.
18. Swinehart JM, Brandy DA. Scalp lifting: anatomic and technical considerations. J Dermatol Surg Oncol 1994; 20:600-612.
19. Epstein JS, Kabaker SS. Scalp flaps in the treatment of baldness: long-term results. Dermatol Surg 1996; 22:45-50.
20. Unger WP. Hair transplantation. New York: Marcel Dekker; 1995.
21. Sasagawa M. [Hair Transplantation.] Jpn J Dermatol 1930; 30:473. *In Japanese.*
22. Okuda S. [Clinical and experimental studies of transplantation of living hairs.] Jpn J Dermatol Urol 1939; 46:135-138. *In Japanese.*
23. Tamura H. [Pubic hair transplantation.] Jpn J Dermatol 1943; 53:76. *In Japanese*.
24. Orentreich N. Autographs in alopecias and other selected dermatologic conditions. Ann NY Acad Sci 1959; 83:463-479.

25. Rassman WR, Carson S. Micrografting in extensive quantities; the ideal hair restoration procedure. Dermatol Surg 1995; 21:306-311.
26. Camacho F, Montagna W. Trichology: Diseases of the pilosebaceus follicle. Madrid: Aula Medica; 1997.
27. Kuster W, Happle R. The inheritance of common baldness: two B or not two B? J Am Acad Dermatol 1984;11:921-926.
28. Bernstein RM. Measurements in hair restoration. Hair Transplant Forum Intl 1998; 8(1):27.
29. Norwood OT. Male pattern baldness: classification and incidence. So Med J 1975; 68:1359-1365.
30. Ludwig E. Classification of the types of androgenetic alopecia (common baldness) occurring in the female sex. Br J Dermatol 1977; 97:247-254.
31. Olsen EA. Female pattern hair loss. J Am Acad Dermatol 2001; 45(3):S70-S80.
32. Chartier MB, Hoss DM, Grant-Kels JM. Approach to the adult female patient with diffuse nonscarring alopecia. J Am Acad Dermatol 2002; 47(6):809-818.
33. Bernstein RM, Rassman WR: The scalp laxity paradox. Hair Transplant Forum Intl 2002; 12(1):9-10.
34. Beehner M. Nomenclature proposal for the zones and landmarks of the balding scalp. Dermatol Surg 2001; 27:375-380.
35. Seager, D. The 'one-pass hair transplant' – a six-year perspective. Hair Transplant Forum Intl 2003; 12(1):176-178, 194-196.
36. Salasche SJ, Bernstein G, Senkarik M. Surgical anatomy of the skin, Norwalk, Conn.: Appleton & Lange; 1988:151-162.
37. Beehner M. Where is thy crown, your majesty? Hair Transplant Forum Intl 1998; 8(1):18-19.
38. Haas A, Grekin R. Antibiotic prophylaxis in dermatologic surgery. J Am Acad Dermatol 1995; 32:155-176.
39. Drake LA, Ceilley RI, Cornelison RL, et. al. Guidelines of care for office surgical facilities, part I. J Am Acad Dermatol 1992; 26(5):763-765.
40. Drake LA, Ceilley RI, Cornelison RL, Dinehart SM, et. al. Guidelines of care for office surgical facilities, part II. Self-assessment checklist. J Am Acad Dermatol 1995; 33(2):265-270.
41. Fader DJ, Johnson TM. Medical issues and emergencies in the dermatology office. J Am Acad Dermatol 1997; 36(1):1-16.
42. Sebben, JE. Survey of sterile technique used by dermatologic surgeons. J Am Acad Dermatol 1988; 18(5):1107-1112.
43. Sebben, JE. Sterile technique in dermatologic surgery: what is enough? J Dermatol Surg Oncol 1988; 14(5):487-489.
44. Bernstein RM, Rassman WR. Dissecting microscope versus magnifying loupes with transillumination in the preparation of follicular unit grafts: a bilateral controlled study. Dermatol Surg 1998; 24:875-880.
45. Blugerman G, Schavelzon D. Ergonomics applied to hair restoration. Hair Transplant Forum Intl 1996; 6(6):1-14.
46. Bernstein RM, Rassman WR: Limiting epinephrine in large hair transplant sessions. Hair Transplant Forum Intl 2000; 10(2):39-42.
47. Bernstein RM, Rassman WR: Wall mounted placing stand. Hair Transplant Forum Intl 1997; 7(4):17-18.
48. Limmer BL. Micrograft survival. In: Stough DB, Haber, RS, eds. Hair replacement: surgical and medical. St. Louis: Mosby; 1996:147-149.

49. Raposio E, Cella A, Panarese P, et al. Power boosting the grafts in hair transplantation surgery. Evaluation of a new storage medium. Dermatol Surg 1998; 24:1342-1346.
50. Krugluger W, Moser K, Hugeneck J, Laciak K, Moser C. New storage buffers for micrografts enhance graft survival and clinical outcome in hair restoration surgery. Hair Transplant Forum Intl 2003; 13(1):325, 333-334, 343.
51. Grekin R, Auletta M. Local anesthesia in dermatologic surgery. Am Acad Dermatol 1988; 19:599-614.
52. McCaughey W. Adverse effects of local anesthetics. Drug Safety 1992; 7:178-189.
53. Skidmore R, Patterson J, Tomsick R. Local anesthetics. Dermatol Surg 1996; 22:520
54. Foster C, Aston S. Propranolol-epinephrine interaction: a potential disaster. Plast Reconstr Surg 1983; 72(1):74-78.
55. Weber P, Weber R, Dzubow L. Sedation for dermatologic surgery. J Am Acad Dermatol 1989; 20:815-826.
56. Goodman AG, Gillman LS. The pharmacological basis of therapeutics, 7th ed. New York: Macmillan; 1985:151-159.
57. Bernstein RM, Rassman WR: Hemostasis with minimal epinephrine. Hair Transplant Forum Intl 1999; 9(5):153.
58. Bernstein RM, Rassman WR, Rashid N: A new suture for hair transplantation: Poliglecaprone 25. Dermatol Surg 2001; 27(1):5-11.
59. Bennett RG: Selection of wound closure materials. J Am Acad Dermatol 1988; 18:619-637.
60. Moy RL, Waldman B, Hein DW: A review of sutures and suturing techniques. J Dermatol Surg Oncol 1992; 18:785-795.
61. Arnold J: Mini-blades and a mini-blade handle for hair transplantation. Am J Cosm Surg 1997; 14(2):195-200.
62. Seager D. Dense hair transplantation from sparse donor area – introducing the "follicular family unit." Hair Transplant Forum Intl 1998; 8(1):21-23.
63. Tykocinski A: A one-year study of using exclusively 'follicular grouping grafts' in specific areas to increase hair density and volume during FUT. Hair Transplant Forum Intl 2003; 13(4):366, 369-700.
64. Limmer BL. The density issue in hair transplantation. Dermatol Surg 1997; 23:747-750.
65. Bernstein RM, Rassman WR, Rashid N, Shiell R: The art of repair in surgical hair restoration – part I: basic repair strategies. Dermatol Surg 2002; 28(9):783-794.
66. Bernstein RM, Rassman WR, Rashid N, Shiell R: The art of repair in surgical hair restoration – part II: the tactics of repair. Dermatol Surg 2002; 28(10):873-893.
67. Choi YC, Kim JC: Single hair transplantation using Choi hair transplanter. J Dermatol Surg Oncol 1992; 18:945-948.
68. Rassman WR, Bernstein RM. Rapid Fire Hair Implanter Carousel: A new surgical instrument for the automation of hair transplantation. Dermatol Surg 1998; 24: 623-627.
69. Boudjema P: A new hair graft implanter: the hair implanter pen. Hair Transplant Forum Intl 1998; 8(4):1-4.
70. Rassman WR, Bernstein RM. The automation of hair transplantation: past, present, and future. In: Harahap M, ed. Innovative techniques in skin surgery. New York: Marcel Dekker; 2002:489-502.
71. Meza DP: Complications in hair restoration surgery. Hair Transplant Forum Intl 2000; 10(5):145.
72. Fader DJ, Johnson TM. Medical issues and emergencies in the dermatology office. J Am Acad Dermatol 1997; 36:1-16.
73. Greco J. The H-factor in micrografting procedures. Hair Transplant Forum Int 1996; 6:8-9.
74. Cooley J, Vogel J. Loss of the dermal papilla during graft dissection and placement: another cause of X-factor? Hair Transplant Forum Intl 1997; 7:20-21.

75. Gandelman M, Mota AL, Abrahamsohn PA, De Oliveri SF. Light and electron microscopic analysis of controlled injury to follicular unit grafts. Dermatol Surg 2000; 26:31.
76. Headington JE. Telogen effluvium: new concepts and review. Arch Dermatol 1993; 129:356-363.
77. Limmer BL, Razmi R, Davis T, Stevens C. Relating hair growth theory and experimental evidence to practical hair transplantation. Am J Cosmet Surg 1994; 11:305-310.
78. Bernstein RM. Blind graft production: value at what cost? Hair Transplant Forum Int 1998; 8:28-29.
79. Bernstein RM, Rassman WR. Follicular unit graft yield using three different techniques. Hair Transplant Forum Int 2001; 11:1; 11-13.
80. Marritt E, Dzubow L. The isolated frontal forelock. Dermatol Surg 1995; 21:523-538.